

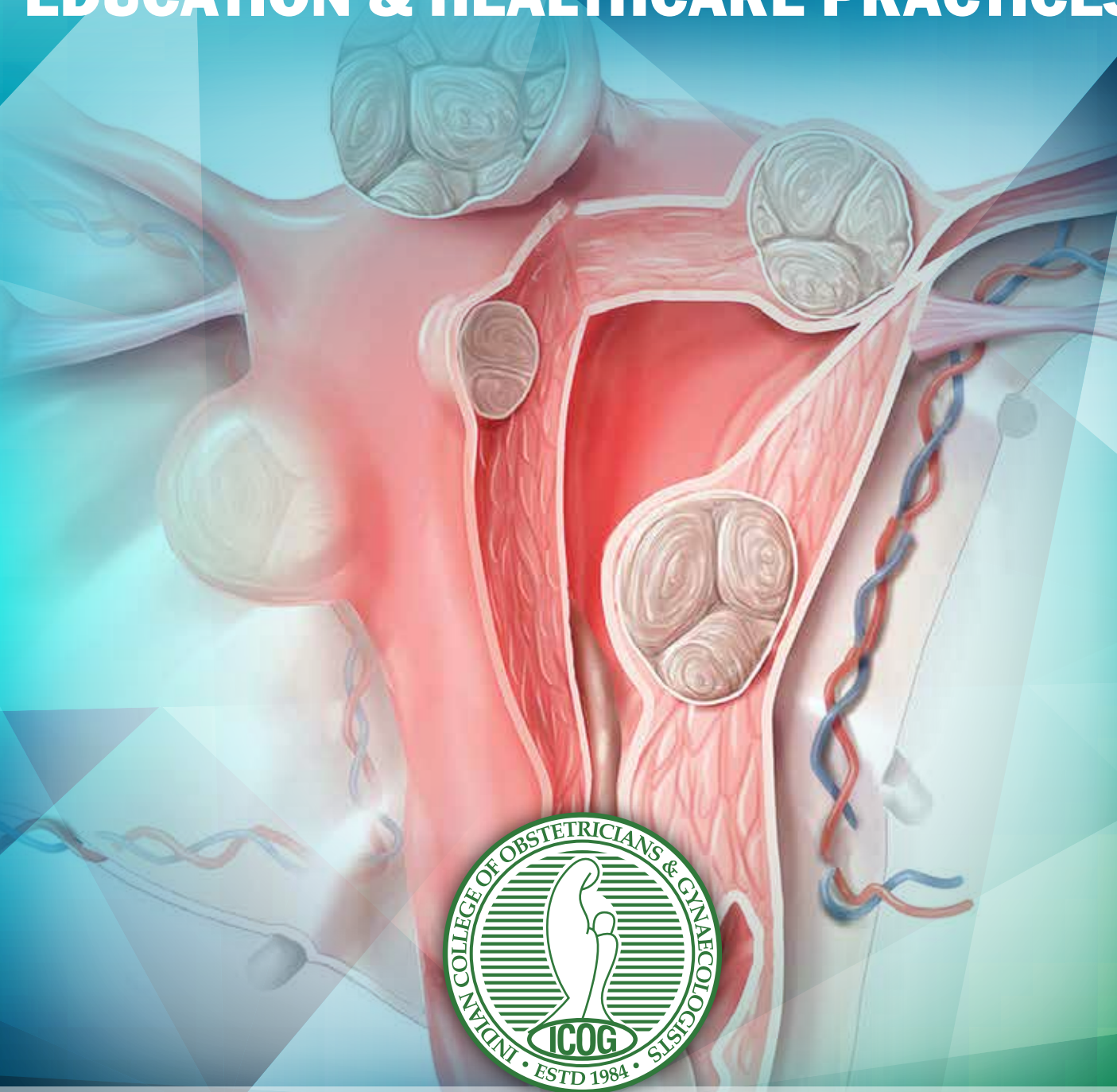


# ICOGG

## CAMPUS



ADVANCING STANDARDS OF  
**EDUCATION & HEALTHCARE PRACTICES**



## **Managing Myomas: An Update**

# President's Address ■■■



**Dr. Rishma Dhillon Pai**  
President FOGSI

“The more I live, the more I learn.  
The more I learn, the more I realize, the less I know.”

— Michel Legrand

**D**ear Colleagues,  
It gives me a great pleasure to know that the newsletter of the ICOG is being released on the subject of myomas. This year under the leadership of Dr. Mala Arora, the ICOG has been very active academically and this new activity of the newsletter has become extremely popular.

The myomas are commonly seen in our practice, yet even today there are many controversies about its management. Today we have many alternatives besides myomectomy and hysterectomy for the treatment of myomas. Medical therapy is being increasingly used. Also, alternative therapies like MRgFUS, Embolization etc also have a significant role to play. The management of myomas in infertility is even more controversial.

I congratulate team ICOG, once again for an excellent newsletter and wish them all the best.

---

# Chairperson's Address ■■■



**Dr. Mala Arora**  
Chairperson ICOG  
chairpersonicog@gmail.com

**H**istorically the commonest benign tumor of the uterus is the innocent looking leiomyoma. However its management is still riddled with controversies. Its presentation is equally common with pregnancy as it is with subfertility. It may present with abnormal uterine bleeding, which may be torrential, but may be just an incidental diagnosis on imaging.

For submucousmyomas and subserousmyomas presenting with pressure symptoms on the urinary tract, surgical excision is non controversial.

However for intramural myomas we may choose to simply keep under observation, treat medically, perform arterial embolization or excise them surgically depending on the presenting complaints and the myoma size and progression.

There are a host of medical management options that range from progesterones, antiprogesterones, and selective progesterone receptor modulator like ulipristal acetate. These not only control abnormal uterine bleeding but also prevent further growth of the myoma and may also cause some regression.

LNG intrauterine system is also a promising substitute of the above oral medications.

Uterine artery embolization is minimally invasive and causes permanent shrinkage of the myoma and is beneficial in solitary large intramural myomas.

Laparoscopic excision is employed widely but in the rare event of sarcomatous changes within the capsule, morcellation may lead to intraperitoneal seedlings which worsen the prognosis.

This issue tries to summarize recent guidelines on above controversial issues along with a brilliant journal scan and quiz section.



# Secretary's Message ■■■



The commonest and most benign lesions of the uterus can pose a challenge to the treating obstetrician, infertility specialist and the endoscopic surgeon.

To operate or not to operate is the first challenge in young women of the reproductive age group with intramural myomas.

To remove it during routine surgery / cesarean section is also fraught with challenges.

Does medical management actually change the outcome is debatable.

These issues need more evidence. This issue brings you the latest on surgical and non surgical management options.

I wish happy reading to all of you.

## ICOG Office Bearers – 2017



**Dr. Rishma Pai**

PRESIDENT FOGSI-ICOG



**Dr. Mala Arora**

CHAIRPERSON ICOG



**Prof. C. N. Purandare**

DEAN ICOG



**Dr. Hrishikesh D. Pai**

SECRETARY GENERAL FOGSI



**Dr. S. Shantha Kumari**

SECRETARY ICOG



**Dr. Sushma Pandey**

VICE CHAIRPERSON ICOG



**Dr. Uday Thanawala**

VICE CHAIRPERSON ELECT 2017

*If You Are Working On Something That You Really Care About,  
You Don't Have To Be Pushed. The Vision Pulls You.*

*- Steve Job*

# From the Editor's Pen ■■■



EDITOR-IN-CHIEF

## Dr. Monika Gupta

MD, DNB, FICOG, MAMS

Associate Professor, Obgyn

VMMC & Safdarjung Hospital,

New Delhi

FOGSI-Kamini Rao Yuva Orator

Awardee 2016

ICOG Travel Fellowship (ART)

Awardee 2016

Joint Secty, AOGD 2015-16

drmonikagupta@hotmail.com

09312796171

[www.icogonline.org](http://www.icogonline.org)

**G**reetings to All!  
Our next issue, in the series of providing latest information on various important aspects women healthcare, is focused on 'Managing Myomas: An Update'.

Uterine fibroids, or leiomyomas, are the most common benign tumors in women of reproductive age. Although many are detected incidentally on imaging in asymptomatic women, 20% to 50% of women are symptomatic and may wish to pursue treatment.

Expectant management is recommended for asymptomatic patients because most fibroids decrease in size during menopause. Management should be tailored to the size and location of fibroids; the patient's age, symptoms, desire to maintain fertility, and access to treatment; and the experience of the physician. Medical treatment aims to control symptoms in order to replace or delay surgery. This may improve the outcome of surgery and prevent recurrence.

Surgical treatment includes hysterectomy, myomectomy, uterine artery embolization, and magnetic

resonance-guided focused ultrasound surgery.

The intent of this issue of ours is to provide a succinct summary of current understanding and evidence based management of fibroids. The newer concepts of minimally invasive treatment both laproscopically and hysteroscopically are reviewed in detail. Description of newer medical drugs and management algorithm for myomas has been presented as a ready reckoner for clinicians. A research experience in nonsurgical management of adenomyosis by an intervention radiologist has been shared which adds flavor to this issue. Fibroids affecting fertility, journal search and intriguing brainteasers have also been presented to stimulate the readers.

I acknowledge the two guest editors for this issue, Dr. Sunita Tendulkar and Dr. Laxmi Shrikhande who are senior members of ICOG governing council.

*"Reading Is To The Mind,  
As Exercise Is To The Body."*

- Brian Tracy

I would like to wish happy reading to all of you.

## eNEWSLETTER TEAM

EDITOR-IN-CHIEF

**Dr. Monika Gupta**

GUEST EDITORS

**Dr. Sunita Tandulwadkar**

Vice-President FOGSI (2017) • Elected Board Member, ISGE (2013-2017)

Clinical Secretary, Indian Society of Assisted Reproduction (ISAR) • Chief, Ruby Hall IVF & Endoscopy Centre, Pune

**Dr. Laxmi Shrikhande**

Member Governing Council ICOG (2012 - 2017) • Senior Vice President FOGSI 2012

Director-Shrikhande IVF & Surrogacy Centre, Nagpur, Maharashtra

EDITORIAL TEAM

**Dr. Bindiya Gupta**

UCMS & GTB Hospital, Delhi

**Dr. Sharda Patra**

Lady Hardinge Medical College & Smt SK Hospital, New Delhi

**Lt Col (Dr) Reema Kumar**

Army Hospital (Research and Referral), New Delhi

**Dr. Puneet K Kochhar**

Elixir Fertility Centre, Delhi

QUIZ MASTER

**Dr. Abha Rani Sinha**

Chairperson Quiz Committee FOGSI (2015-2017)

# Minimally Invasive Management of Myomas: A Comprehensive Review



**Dr. Urvashi Prasad Jha**

Director & HOD

Department of Minimal & Natural Access  
Gynae Surgery & Gynae Cancer Surgery  
(MNAGCS), Fortis Flt Lt Rajan Dhall Hospital,  
New Delhi



**Dr. Neema Sharma**

Director

Department of Minimal & Natural Access  
Gynae Surgery & Gynae Cancer Surgery  
(MNAGCS), Fortis Flt Lt Rajan Dhall Hospital,  
New Delhi



**Dr. Ramandeep**

Additional Director

Department of Minimal & Natural Access  
Gynae Surgery & Gynae Cancer Surgery  
(MNAGCS), Fortis Flt Lt Rajan Dhall Hospital,  
New Delhi

## LAPAROSCOPIC MYOMECTOMY

### INTRODUCTION

Every judicious gynaecologist who performs operative laparoscopy graduates over time to perform laparoscopic myomectomy only after mastering laparoscopic suturing skills. Ideally, less challenging cases are undertaken first, followed gradually by progressing to more complex cases with larger and more number of myomas at relatively inaccessible sites. It is best, initially, to have a mentor or expert see you through the first few cases by assisting you. Additionally, the discipline of training on the pelvi-trainer is a safe and mandatory preparatory exercise. All of this is to emphasize that the most important factor in performing laparoscopic myomectomy is "surgeon expertise". Different surgeons are bound to report different operating time reflecting their individual learning curve at various times.<sup>1,2,3</sup>

The size, location and number of myomas will continually be the changing criteria for every individual gynaecologist when performing laparoscopic myomectomy. As laparoscopic dexterity and experience improves, so will the complexity of cases successfully and safely completed by them. It is also necessary to recall that the initial experience worldwide of performing laparoscopic myomectomies without appropriate and adequate suturing of the uterine wounds resulted in sad and unnecessary scar ruptures in pregnancy. It earned laparoscopic myomectomy a bad reputation. But "expert" laparoscopic surgeons since then have grown in their expertise by leaps and bounds making it not just a safe and a possible option, but one with advantages over "open" myomectomy. "Each surgeon has to determine selection criteria based on personal proficiency".<sup>4</sup>

## INDICATIONS

The indications for myomectomy remain the same, whether the route is laparoscopy or laparotomy. Hysterectomy is the most effective treatment of myomas. Myomectomy is warranted when hysterectomy is undesirable or future fertility is desired. Myomas have a 15% recurrence rate and 10% of women undergoing a myomectomy will eventually require hysterectomy within 5 to 10 years.<sup>5</sup> Menstrual problems, fertility related issues, fetal wastage or premature delivery, pressure effects on the bladder or bowel, are common indications for myomectomy. Rapidly growing myomas and a large size have currently been included as indications for surgery for the fear of missing sarcomatous changes. Patients with infertility that have recurrent implantation failure also require surgical removal. Having said that, the Society of Gynaecologists of Obstetricians & Gynaecologists of Canada (SOGC) concludes that "rapid growth of a myomas does not seem to be a predictor of leiomyosarcoma. However postmenopausal growth or onset of symptoms should carry a higher index of suspicion for malignancy".<sup>6</sup>

## CONTRAINDICATIONS TO LAPAROSCOPIC MYOMECTOMY

In the experience of Holub, as well as reflected in the literature, a consensus is gradually emerging that laparoscopic myomectomy is safe for myomas not more than four in number with maximal size of 8-10cm.<sup>1</sup> Contraindications to myomectomy by laparoscopic route are

1. Lack of laparoscopic expertise to perform laparoscopic myomectomy and inadequate suturing skills.
2. An anticipated unduly prolonged operating time with its associated risks

of excessive bleeding especially in case of very large (> 10 cm) or multiple leiomyomas.

3. Risks of prolonged anaesthesia time in patients with co morbid conditions.
4. Larger myomas in more difficult locations such as in the lower segment or at the cervical junction.<sup>6</sup>
5. Absence of immediate availability of blood and blood products.

## PREOPERATIVE PREPARATION

1. Counselling and obtaining a fully informed consent prior to performing a laparoscopic myomectomy is of prime importance today.
2. Consent should also be obtained for managing unforeseen but often associated problems of endometriosis, adenomyosis, polyps. A hysteroscopy should be offered particularly in patients with menorrhagia or infertility at the end of the laparoscopy. This can detect unsuspected submucous myomas which may have been pushed into the cavity during or after the removal of large fibroid laparoscopically by myometrial contraction.
3. Explaining the case specific indication: When the patient is seen in the outpatient, it is essential to clarify the reason for performing myomectomy. Discuss the advantages and disadvantages of other surgical and non-surgical treatments as relevant in the particular scenario. The benefits the patient may expect and the possibility of not having some symptoms resolve or recur after surgery must also be clearly understood by the patient.
4. Clarifying Myths about laparoscopy: Myths about laparoscopy propounded by the 'non-believers' that the laparoscopy



may be incomplete or unsafe. It is essential to dispel their doubts at the outpatient consultation itself, before the patient takes a decision. When multiple myomas are present with many small intramural myomas it is mandatory for the patient to understand that some may remain after surgery. This enables reconstitution of remaining uterine muscle tissue into a wholesome uterus rather than leaving a bag of rags they may give way (rupture) during the stretch in pregnancy.

5. Appreciating the advantages of the laparoscopic approach: The laparoscopic approach offers advantages over the traditional approach of smaller more cosmetic incisions, less pain, more precision from the magnification on screen, less blood loss, less postoperative adhesions, early recovery amongst others. Specific to myomectomy is perhaps less bleeding in expert hands, better vision and approach to myomas deep in the pelvis or otherwise not freely accessible at laparotomy and less adhesion formation. Long term problems and fertility issues as a result of adhesion formation are therefore lesser with the laparoscopic approach.<sup>7</sup>
6. Explanation of the complications with the laparoscopic approach. These should be separated into two broad categories- those from the myomectomy procedure itself and those as a result of using the laparoscopic approach. The complications from using laparoscopy as the route of surgery are those at making the verse needle primary port entry. Using a direct port entry under vision obviates these. Problems may also arise from carbon dioxide insufflation. Both of these are difficult to explain to the patient. Suffice to understand that these are very uncommon. The various benefits from using the laparoscopic approach outweigh the rare complications from laparoscopy
7. The patient should also be counselled about the issue of missing small intramural myomas because of the lack of direct tactile sensation in laparoscopy. This can be overcome to some extent by precise delineation of myomas using pre-operative MRI evaluation. Intra operative ultrasound, where available is very useful.
8. A complication often forgotten is the risk of incisional hernia particularly in the port used for morcellation.
9. The risk of a "weak" myomectomy scar is a result of suturing inadequacies, whether it be at laparoscopy or laparotomy. Hence it is all the more important that intramural fibroid be operated laparoscopically only by those who can repair the uterine incisions adequately.
10. At counselling, the surgeon must reassure the patient about having these requisite skills. However it must be understood

that scar rupture can take place despite appropriate suturing.<sup>8</sup> Other factors like hematoma formation, infection and unknown host factors also contribute to the healing process and strength of the uterine scars. Those patients requiring future fertility need this reassurance and explanation so they are vigilant in subsequent pregnancies about these risks.

11. The extremely rare requirement of proceeding to a hysterectomy in the presence of uncontrolled hemostasis or inability to reconstruct the uterus must be explained to the patient and consented for.

## PREOPERATIVE EVALUATION AND MANAGEMENT

1. In addition to the regular panel of preoperative laboratory investigations it is prudent to check that the hemoglobin assessment is recent and not undertaken before the last menstrual period. Anaemia needs correction preoperatively either with oral or parental iron.
2. If the procedure needs to be done as an emergency preoperative blood transfusion may need to be given.
3. Serum CA125 and LDH levels are useful to raise suspicion of sarcomatous changes. In those patients with rapid growth of the fibroid or in perimenopausal women these must be documented preoperatively. If mutually agreed upon with the patient, a frozen section is performed.
4. A good 3D/4D vaginal ultrasound with colour Doppler for delineation the size, number and site of the fibroid as well as any abnormal blood flow. An MRI pelvis with contrast is undertaken for precise localization of the myomas, big or small because reporting of an MRI is less observer dependent than that of an ultrasound.
5. In patients with broad ligament or cervical myomas IVP helps in localizing the position of the ureters relative to the fibroid.

## ANCILLARY TREATMENT PRIOR TO SURGICAL INTERVENTION

**GnRh agonists or selective progesterone receptor modulators:** If surgery needs to be delayed for any reason GnRh agonists or selective progesterone receptor modulators may be used to decrease the size of the myomas. However, planes of dissection become less well defined and degeneration in the myomas makes intraoperative manipulation difficult. However, studies that examined the effects of GnRH agonists on intraoperative blood loss have revealed conflicting results. GnRH agonists have negative side effects as well such as the development of a pseudo-menopausal hypoestrogenic state, and are associated

with a possible increased risk of myoma recurrence. In addition, studies have also shown that agonist therapy can soften myomas, obscuring the cleavage plane between the fibroid and the pseudocapsule, making the surgery more difficult with increased bleeding.<sup>8</sup>

**Uterine Artery Embolisation** on the day before the procedure, particularly in large vascular myomas may be attempted to help decrease blood loss at surgery. It reduces blood loss by about 80-90% due to uterine artery occlusion. Total block may hamper healing. It is particularly useful when in situ morcellation of myomas is planned, to debulk large myomas.

## PREOPERATIVE INSTRUCTIONS:

1. Liquid diet 24 hours to 4 days pre-operatively is used to help with better visibility and more space from collapsed empty bowel loops. Peglec or a laxative can be given the evening before with similar results.
2. In patients with anterior cervical or a previous caesarean section scar the urine may be coloured using pyridium or MVI given the evening before the procedure. It helps to detect urine leak from any inadvertent damage to the ureters or bladder.

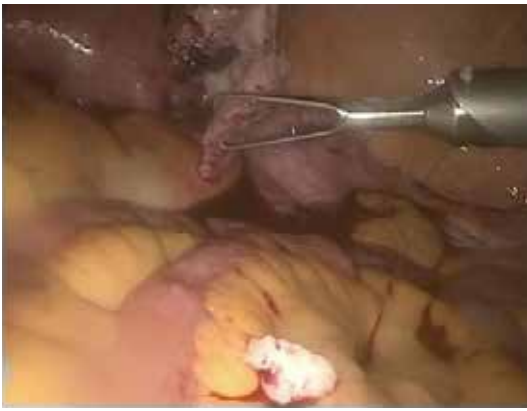## INTRAOPERATIVE REQUIREMENTS

### *Special instruments, sutures and adhesion prevention barriers*

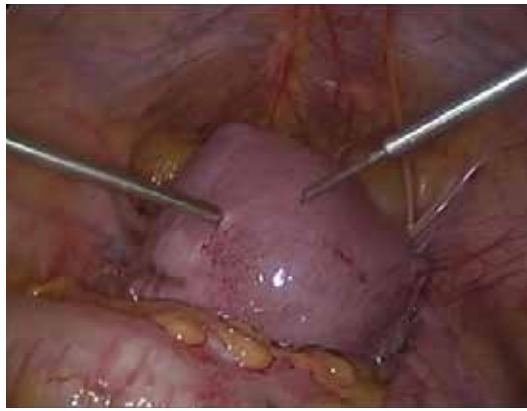It is preferable to have the following instruments ready - Laproscopic tenaculum (Figure 1), or a myoma scoop, laparoscopic injection needles (Figure 2), myoma screws (Figure 3), and a pair of sturdy laparoscopic scissors. Other desirable instruments are harmonic scalpel/hook, Other desirable instruments are harmonic scalpel/hook laparoscopic knife handle, and a morcellator with a spare set of sharp blades (Figure 4). Laparoscopy bags-2 sizes for morcellation of fibroid in a bag, a pair needle holders (preferably one is toothed), Vicryl sutures 1-0 on a large needle and V-lock or quill sutures. A laparotomy set and a set of vaginal instruments should be kept ready for removal of myoma via colpotomy

## POSITIONING OF PATIENT

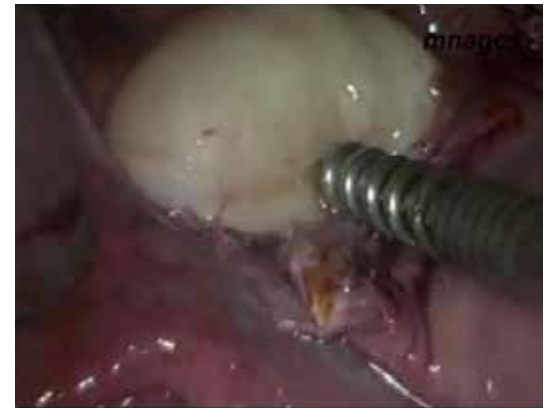1. A low lithotomy position is commonly used. The legs could be placed slightly higher to facilitate a hysteroscopy without the need for repositioning.
2. It is helpful to have the arms by the sides so they don't obstruct the movements of the surgeons.
3. For optimizing ergonomic comfort of the operating team the table should be low enough to allow the arms to slope downwards whilst operating at 45 degree- 60 degree to the horizontal at the shoulder joint.



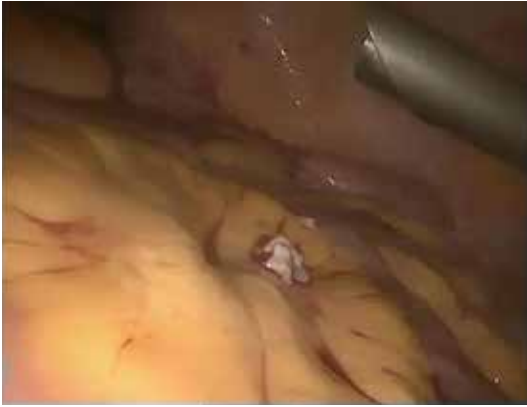**Fig. 1: Laparoscopic tenaculum**



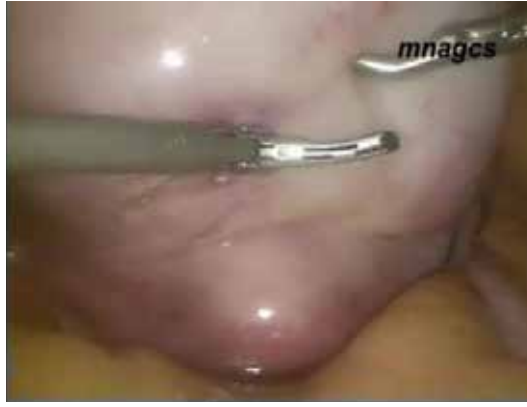**Fig. 2: vasopression injection needle**



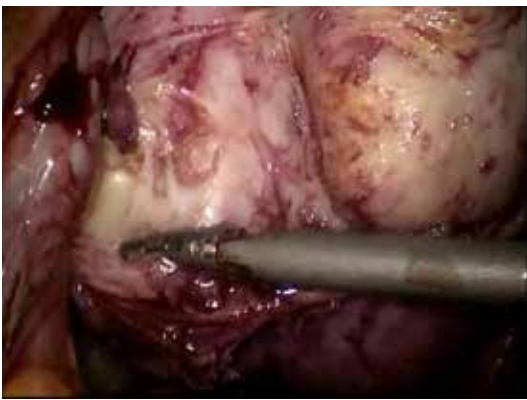
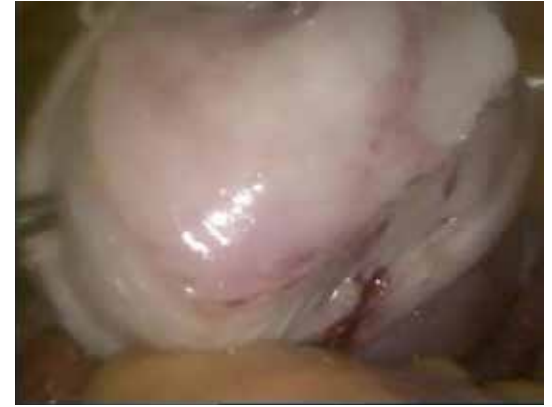**Fig. 3: 5 mm myoma screw**



**Fig. 4: Morcellator**



**Fig. 5 & 6: Elliptical incision**



**Fig. 7: Enblock myomectomy**

This is generally below the level of the surgeon's mid-abdomen.

4. The patient should either be on a non-slip mattress or have adequate shoulder support to prevent the patient sliding down during the head-down position.
5. During primary entry, the abdomen is flat parallel to the ground. After all the ports are placed the steep trendelenberg position is recommended.
6. Intra operative pneumatic cuff compression device is used on the legs for thromboprophylaxis.
7. Long intravenous lines are setup to allow access to the anesthetist at the head end since the arms are by the side,
8. A nasogastric tube is placed to enable gastric emptying if a high primary entry site is planned in the epigastric abdominal quadrant to prevent stomach injury.

#### PLANNING TROCAR ENTRY

1. The telescopic port site is variable. It should be supraumbilical at least four inches above the highest myoma.

2. A Palmer's point/Lee Wang's/Jha's left epigastric entry site is useful. The higher the site the better the vision provided. It also gives a good bird's eye view of the operative field (myomas will rise higher during the enucleation process as they are disengaged from the uterine bed). This allows smooth manipulations of instruments above the uterus.
3. The accessory ports may be 2 or 3 or 4 depending on surgeon preference, the position of the myomas and whether the surgeon operates using ipsilateral or contralateral ports.
4. Usually an additional port to manipulate the uterus, with 1 or 2 myoma screws is a huge advantage.
5. Inspect the abdominal cavity for site, size and number of fibroid and for any additional pathology.

#### PLANNING THE UTERINE INCISIONS

1. In intramural single or myomas placed well apart from each other, a single incision over the area of maximum convexity in horizontal or vertical planes may be used as appropriate. The advantage of horizontal or transverse incisions is that they run along the vascular branches arising from the uterine arteries and bleed less. Moreover, suturing is easier in the horizontal plane, particularly with the use of contralateral ports.
2. The option of making an elliptical incision (Figures 5 & 6) instead of a linear one may be exercised to reduce dissection time, bleeding and combine it with excision of the redundant myohyperplastic tissue at one go.

3. The healing of a scar and subsequent rupture in pregnancy are reputed to be dependent on the use of good microsurgical principles of uterine wound closure in layers. Excessive necrosis by strangulating sutures or from the use of energy is detrimental to healing. Six months should be allowed for the recovery and adequate healing of the scar. There is no data available correlating the excision of excess myometrial tissue with the risk of uterine rupture, as long as approximation of the myometrium is not under tension. Recently, the use of bidirectional barbed suture, Quill, (Angiotech, Vancouver British Columbia) has been proposed to assist with approximation of myometrial defects. Proposed benefits include more evenly distributed wound tension and obviation of the need for knot tying.<sup>10</sup>
4. With multiple myomas conglomerated together, en-block myomectomy can be undertaken by using the elliptical incision over the myomas closest to the uterine cavity and leaving enough myometrium to refashion the uterine wall, whether anteriorly, posteriorly or superiorly. (Figure 7) "One uterine incision is advised for the removal of multiple leiomyomas. Though microsurgical closure of the myometrial defect can be difficult, the goal should be good approximation without strangulation".<sup>9</sup>
5. The origin of the 3 fundal structures-round ligament, fallopian tubes and ovarian ligaments are useful superior landmarks to guide the incision, particularly in situations where the three may be variably splayed apart. The cervix and attachment of uterosacral ligaments is the inferior land mark, especially in



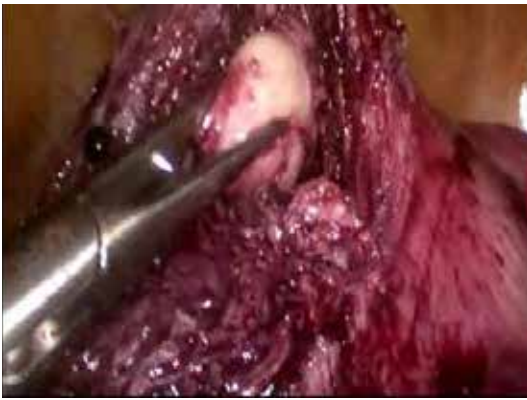

Fig. 8: Tunnelling of anterior wall fibroid

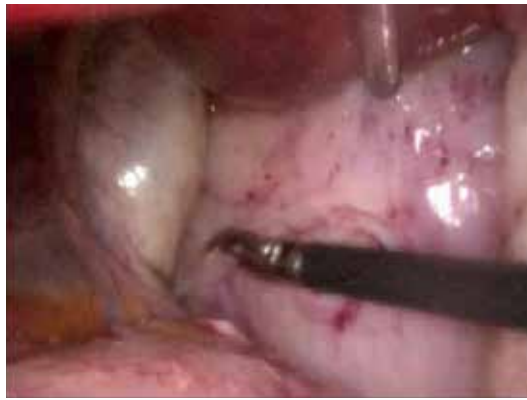

Fig. 9: Large cervical fibroid

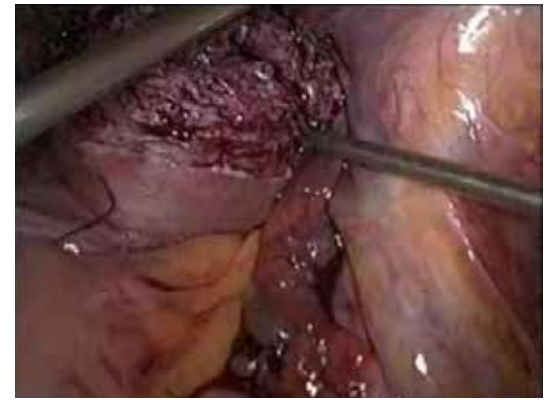


Fig. 10: Myoma bed

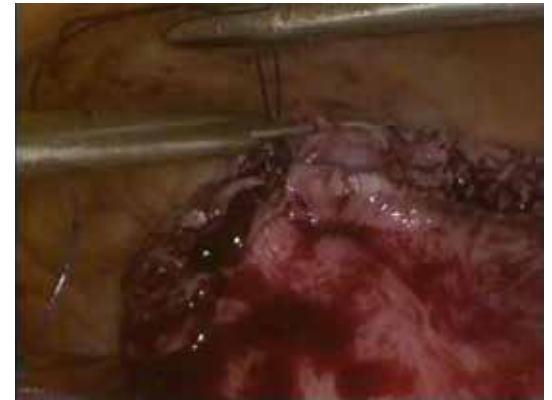

Fig. 11: Suturing of myoma bed

situations where it is not distorted grossly by cervical or lower uterine myomas.

- One must be careful to allow for significant myometrial retraction after the myomas are enucleated. It is better to err on the side of taking less away than more. There must be more than enough myometrial tissue to allow reconstruction of the sutures by approximating sutures that are not under tension. If excessive myometrium is left behind without menorrhagia being a significant symptom, double breasting of the incision is also an option.

Tunnelling of myomas (Figure 8) through the primary uterine incision preserves the serosal surface. Multiple incisions on the uterine serosa are thus avoided decreasing significantly the risk of adhesion formation

- If during tunnelling or otherwise the endometrial cavity is inadvertently opened, it must be inspected and palpated to detect any associated submucous myomas. These can then be removed through the uterine scar using a myoma screw for enucleation prior to closure of the uterine incision.
- Anterior cervical lower uterine myomas (Figure 9) should be approached after opening the uterovaginal fold and pushing the bladder down. This will also safeguard the ureters.
- Low posterior cervical myomas too will need to be approached using uterosacral ligaments as landmarks and dissecting the rectum away from the field. Identifying the ureters is mandatory.
- Similarly broad ligament myomas should be approached after tracing the ureters and determining whether it is a true or false broad ligament fibroid. The ureter traversing through the substance or between 2 apposing myomas in the broad ligament is a particularly challenging situation and ureteric catheterization is an option.

Preoperative imaging by MRI and an IVP in such situations is a useful safeguard. Minimising the number of uterine incisions will decrease the postoperative adhesions to the uterine serosa and increase myometrial integrity. Additionally it is good practice to intermittently reorient oneself to the distorted anatomy of the uterus and pelvic structures to prevent inadvertent damage.

## PRACTICES THAT DECREASE INTRAOPERATIVE BLEEDING

Blood loss at myomectomy can be decreased by

- Injecting vasopressin into the uterus, dilute vasopressin (Pitressin: 1 ampule of 20 IU in 60-100 mL lactated Ringer's solution) decreases the amount of blood loss<sup>9</sup> or bupivacaine, epinephrine, misoprostol, gelatine, thrombin matrix.
- Use of additional hemostatic agents such as a gelatin-thrombin matrix have been reported to be useful in achieving hemostasis and can be applied easily to the suture line during laparoscopy.<sup>11</sup>
- Uterine artery ligation, with an absorbable suture, before starting myomectomy was pioneered and popularised by the late Dr Rakesh Sinha. It is of particular benefit with large myomas.
- Uterine artery embolization within 24 hours of undertaking laparoscopic myomectomy is under clinical trial. Collateral circulation has been demonstrated to develop thereafter.
- Most important however is placing adequate deep sutures in between without strangulating tissue and without leaving dead space or allowing hematoma formation from inappropriately placed loose suturing.

## STEPS OF MYOMECTOMY

- Making the incision:** After planning the incision sites and injecting the diluted vasopressin at the base of subserosal myomas or into the intramural myomas by using 1 or more sites for injecting, the incision is made using a laparoscopic scissor, knife, harmonic blade or hook deep in the myometrium till the interface between the fibroid and the pseudocapsule using a myoma screw manipulating the fibroid and facilitates making of the incision. The width of the incision varies with the size of the lesion. In case of large pedunculated and subserosal fibroid, a circumferential incision is made leaving enough capsule for suturing the myoma bed. Care should be taken to ensure that the incision does not extend to the cornual end of the fallopian tubes<sup>4</sup>.

- Enucleation:** Using traction of the fibroid with the myoma screw and counter traction on the uterus by holding the myometrium with toothed forceps and steadying the uterus from below via the vulsellums holding the cervix, enucleation is performed. Using the specially designed scoop, suction irrigation probe or closed jaws of the harmonic helps dissection. Bleeders or adhesions are focally cauterized and incised as seen, to minimize blood loss. After removal of the presenting fibroid, deeper myomas may be removed in a similar manner by approaching them through the primary incision by tunnelling if appropriate. A degenerated fibroid may be too friable to allow a firm grip with a myoma screw<sup>4</sup>. If the uterine cavity is opened, the endometrium is repositioned and the uterine wall is closed excluding the endometrium.<sup>4</sup>

- Debridement of excessive myometrial tissue:** Any redundant myometrial tissue flapping over the incision may either be debrided or preserved for double breasting. For those who argue against debridement, it is relevant to note that no data or level 1 or 2 data exists to support the claim that appropriate debridement predisposes to subsequent uterine rupture in pregnancy.

- Suturing the uterine wound:** The principles of uterine incision suturing include proper approximation of tissues without leaving any dead spaces. (Figures 10, 11) On the other hand inadequate and inappropriate suturing without approximation predispose to a weak scar. The sutures may be deep interrupted, figure of eight, mattress, continuous, continuous locking



or baseball. Advantage of minimizing the exposed suture material is to decrease the risk of adhesion formation. The suture material used is either vicryl number 1, 1-0 or 2-0. To help maintain appropriate tension without strangulation and to obviate the need for knotting skills-barbed sutures have been developed and are extremely popular. To ensure that the sutures go through the depth of the incision, 4/5 cm ½ curved needles are helpful. Irrigation with warm saline not only clears any remaining debris but highlights bleeding points. A drain may be left if hemostasis is not complete.

e. **Removal of myomas:** Preoperative counselling and consent about this aspect of procedure is very essential. The removal after morcellation of myomas has come

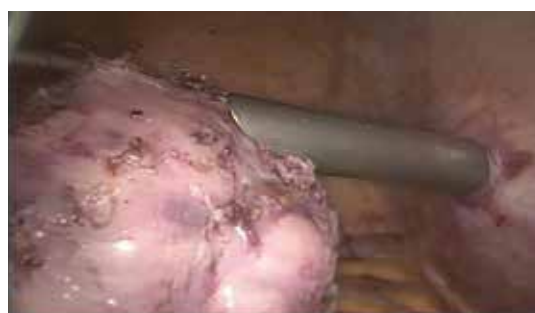

Fig. 12: Morcellation of fibroid

under a lot of fire because of the small risk of the fibroid being an unsuspected leiomyosarcoma. This could then be upstaged with early recurrence or spillage may also initiate the development of parasitic myomas and adenomyomas.<sup>12,13</sup>

When morcellation is necessary to remove the specimen, the patient should be informed about possible risks and complications, including the fact that in rare cases fibroid(s) may contain unexpected malignancy and that laparoscopic power morcellation may spread the cancer, potentially worsening their prognosis.<sup>6</sup>

For laparoscopic morcellation, spillage may be minimized by placing the specimen in a bag (Figure 12) and using the mechanical morcellator inside the bag. However use of a bag may limit visualization and has not been well studied. For larger specimens, a mini-laparotomy with or without use of self-retaining retractor can be performed and the specimen be morcellated mechanically or with a scalpel blade within a bag. If the specimen is delivered vaginally and requires morcellation, again a bag can be used to enclose it to minimize spillage.<sup>14,15</sup>

With large or calcified myomas, the

morcellator blade may grow dull necessitating the use of multiple devices. This leads to additional financial and ecological costs especially when multiple disposable instruments are used.<sup>9</sup>

## ADHESION PREVENTION

Using good microsurgical techniques of dissection and suturing go a long way in adhesion prevention as does burying of sutures or minimising exposed suture material. Ensuring good hemostasis and preventing infection are equally important.<sup>16</sup> Adhesion prevention barriers popularly used are interseed. Nezhath popularising spraying 10,000 IU of thrombin over the interseed.<sup>9</sup>

## PREVENTION OF PAIN AND DVT

We have found instilling sensoricaine in diluted in 100 ml saline over the uterine wound, in the pelvis and injecting it at the abdominal wound sites helpful in decreasing post-operative pain along with early mobilisation.

Perioperative DVT prophylaxis is ensured by starting LMWH subcutaneously the night before surgery and continuing for 7-10 days postoperatively.

## POSTOPERATIVE MONITORING

Postoperative monitoring by vaginal sonography is a good idea to detect hematoma formation or the presence of a weak scar. It also detects residual fibroid which may need to be put under surveillance.

## HYSTEROSCOPIC MYOMECTOMY

Hysteroscopic myomectomy is the standard minimally invasive procedure for treating submucosal myomas.<sup>17</sup>

## INDICATIONS FOR HYSTEROSCOPIC MYOMECTOMY

1. AUB since submucous myomas lead to distortion of the cavity and increase in the bleeding surface of the endometrium.<sup>18</sup>
2. Pregnancy loss or impaired fertility -Submucous myomas may exert detrimental effects on pregnancy rates.<sup>19</sup> It may due to focal endometrial vascular disturbances, endometrial inflammation, secretion of vasoactive substances or an enhanced endometrial androgen environment.<sup>20,21</sup>
3. Less frequent reported indications include dysmenorrhea,<sup>22</sup> nonspecific pelvic pain<sup>23</sup> and asymptomatic submucous fibroid in a woman candidate to start hormone replacement therapy.

## PRE OP ASSESSMENT

1. Preoperative evaluation of submucosal myomas is important to minimize the incidence of incomplete resection and

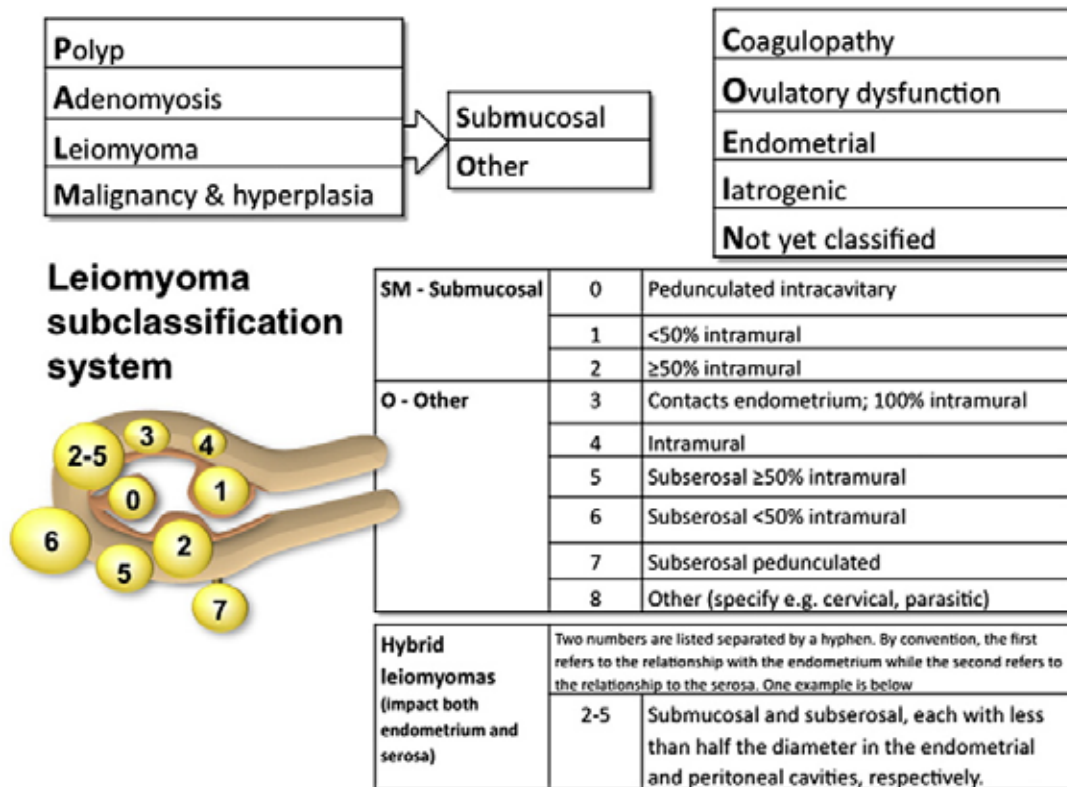
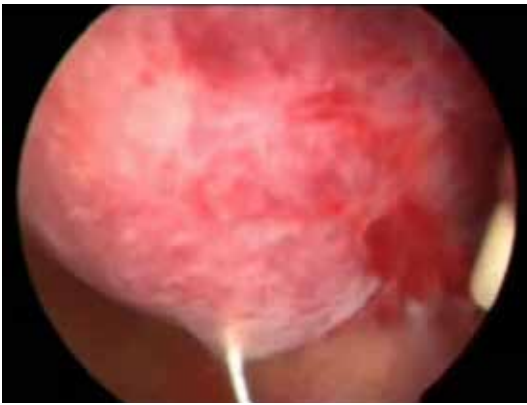

Fig. 13: FIGO classification of submucous leiomyomas<sup>24</sup>

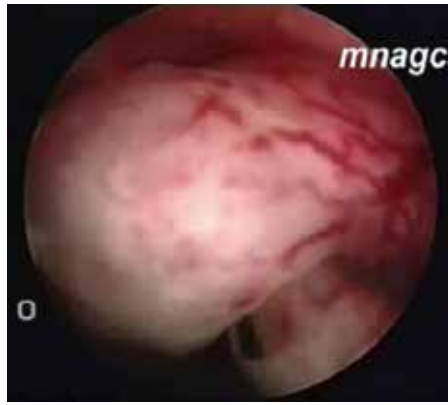Table 1: Presurgical Lasmar score classification of submucous myomas<sup>25</sup>

Points	Penetration of myometrium	Largest myoma diameter	Extension of myoma base to endometrial cavity surface	Location along uterine wall	Lateral wall involvement
0	0	<2cm	<1/3	Lower	Absent
1	<50%	2 to 5cm	<1/3 to 2/3	Middle	Present
2	>50%	>5cm	>2/3	Upper	

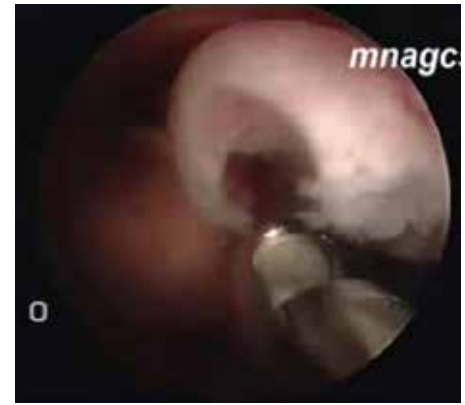It refers to the extension of the base of the nodule with respect to the uterine wall on which the myoma is located. Score 0-4 (Group I): low complexity hysteroscopic myomectomy. Score 5-6 (Group II): complex hysteroscopic myomectomy, consider preparing with GnRH analogue and/or two stage surgery. Score 7 - 9 (Group III): recommend an alternative non-hysteroscopic technique



**Fig. 14: Resection of the fibroid using resectoscope**



**Fig. 15,16 : Using Intrauterine Morcellator (IUM)**



complications. It can be evaluated by office hysteroscopy, transvaginal ultrasound scanning (TVS) and sono hystero-graphy (SHG).

2. TVS is important in the preoperative assessment as it provides the 'myometrial free margin' (thickness of the outer myometrial layer of the fibroid which should be at least 1 cm thick) as well as the presence of any other possibly associated pathology
3. MRI can provide valuable information in case of a large uterus, with multiple myomas, or if ultrasound scanning is technically difficult (i.e. obese patients), also helpful in differentiating between myomas and adenomyosis. MRI can also measure the myometrial free margin with less observer errors compared to TVS.
4. Various classifications are available to decide the management of myomas. (Figure 13, Table 1)

## PRE-OP PREPARATION

The cervix may be softened to facilitate cervical dilatation by the use of 400 microgram misoprostol a few hours before the procedure. Prophylactic antibiotics has no benefit in hysteroscopic procedures. Possible exceptions might include surgery in women with a past history of pelvic inflammatory disease.<sup>26</sup>

## MYOMECTOMY TECHNIQUES

There are 3 basic methods for removing leiomyomas

1. Loop electrosurgical resection
2. Vaporization.
3. Hysteroscopic morcellation

**Loop electrosurgical resection** is performed with the electrode activated with cutting current to allow the repetitive creation of "strips" of myoma. These chips can be removed manually with the sponge holding forceps. End of the procedure is when the fasciculate pink structure of the myometrium is visualized. (Figure 14)

This can be used for type-0 and most type-1 lesions but for deep type 1 and type 2 lesions there may be a role for the concomitant

performance of laparoscopy to reduce the chance of perforation and it also allows for the creation of a safe buffer of gas around the uterus should perforation occur. Alternatively, it can be done under USG guidance.<sup>27</sup>

**Vaporization** In a pedunculated fibroid, the basis of the pedicle might be cut by resectoscopic loop or Nd:yAG laser or vaporizing electrode. The resected node is then usually extracted with forceps.

## MORCELLATION BY INTRAUTERINE MORCELLATOR (IUM)

Recently, Emanuel and Wamsteker (2005) have conducted a retrospective comparison between this technique and conventional resectoscopy and has found it effective for the treatment of G0 and G1 myomas (Figures 15, 16). It is faster as aspiration of tissue fragments through the instrument allowed the surgeons to save much time. However, further data are needed to evaluate long-term follow-up and to demonstrate whether this might result in fewer fluid-related complications.<sup>28</sup>

## COMPLICATIONS

These are broadly those associated with performing hysteroscopy and those specific to the procedure of myomectomy.

1. Uterine perforation can occur with dilators, grasping tools, or with the resectoscope. If perforation occurs with mechanical instruments, and no bowel injury is suspected, the patient can be observed expectantly. Laparoscopy should be reserved if perforation occurs with an activated electrode where bowel injury is suspected, where there appears to be a large defect, or in the presence of heavy bleeding.
2. Complications due to distension media.

The goals of fluid management include: (1) prevention of excess absorption; (2) early recognition of excess absorption; and (3) choosing the distending medium least likely to cause complications in the event of excess absorption. The use of normal saline combined with bipolar energy reduces the risk of hyponatremia but an excessive intravasation (1500

ml) still remains a risk and might cause cardiac overload.<sup>29</sup>

3. Intracervical injection of agents that cause uterine contraction, such as vasopressin<sup>30</sup> and the prostaglandin F2a agonist carboprost<sup>31</sup> have also been shown to decrease fluid absorption.
4. Bleeding: Intracervical injection of a prostaglandin F2a analog causes uterine contraction and control of bleeding<sup>14</sup>. Bleeding can also be treated by the placement of a Foley catheter/balloon into the endometrial cavity, inflating it with sufficient saline.
5. Another option for controlling bleeding is uterine artery embolization with interventional radiologic techniques. Finally packing the uterus with vasopressin-soaked gauze has been described for the management of severe cases.<sup>32</sup>
6. Post-operative intrauterine adhesions (IUA)

The risk of post-operative IUA can be avoided by minimizing trauma of healthy endometrium and myometrium surrounding the fibroid, reducing the usage of electrosurgery especially during the removal of myomas with extensive intramural involvement and multiple myomas on opposing endometrial surfaces An early second-look hysteroscopy after any hysteroscopic surgery is another effective preventive and therapeutic strategy .Several pharmacologic (conjugated estrogen, levonorgestrel- releasing intrauterine device) and barrier agents, including foley catheter, hyaluronic acid gel and hyaluronic acid and carboxy methylcellulose (Seprafilm) have been used to reduce IUA development. A recent review has clearly indicated that there is no single modality proven to be unequivocally effective at preventing post-operative adhesion formation for hysteroscopic surgery.<sup>33</sup>

## CONCLUSION

Laparoscopy and hysteroscopy have several advantages over the open abdominal route for myomectomy. All gynaecologists should ensure their patients benefit from



these techniques whether they perform the procedures themselves or get a trained colleague to do so for them. Ideally they should push and train themselves in performing advanced endoscopic procedures incorporating them eventually into their own routine practice.

## REFERENCES

- Holub Z. (2007): Laparoscopic myomectomy: Indications and limits. *CeskaGynekol* 72(1):64-8
- Kolkman W, Wolterbeek R, Jansen F. Implementation of advanced laparoscopy into daily gynecologic practice: difficulties and solutions. *J Minim Invasive Gynecol*. 2006;13:4e9.
- Kolkman W, Engels LE, Smeets MJ, Jansen FW. Teach the teachers: an observational study on mentor traineeship in gynecological laparoscopic surgery. *GynecolObstet Invest*. 2007;64:1e7.
- Laparoscopic management of large myoma. Rakesh Sinha and Meenakshi Sundaram. *J GynecolEndoscSurg* 2009 July- Dec 1(2):73-82.
- Garcia CR. Management of the symptomatic fibroid in women older than 40 years of age: hysterectomy or myomectomy? *ObstetGynecolClin North Am* 1993;20:337-48.
- George A Vilos, MD, London ON Catherine Allaire, MD The management of uterine leiomyomas. *J ObstetGynaecol Can* 2015;37(2):157-178
- Herrmann A, De Wilde RL. Laparoscopic myomectomy: The gold standard *Gynecology and Minimally Invasive Therapy*. 2014; 31e38
- Parker WH, Einarsson J, Istre O, Dubuisson JB. Risk factors for uterine rupture after laparoscopic myomectomy. *J Minim Invasive Gynecol*. 2010;17: 551e554.
- Nezhat C, Nezhat F, Silfen SL, et al. Laparoscopic myomectomy. *Int J Fertil* 1991;36:275.
- Greenberg JA, Einarsson JI. The use of bidirectional barbed suture in laparoscopic myomectomy and total laparoscopic hysterectomy. *J Minim Invasive Gynecol*. 2008 Sep-Oct;15(5):621-3.
- Linsky CB, Diamond MP, Dizerega GS. Effect of blood on the efficacy of barrier adhesion reduction in the rabbit uterine horn model. *Infertility*. 1988; 11:273.
- RefSizzio, Rossetti A, along M, Minelli L, La Grattaf et Al. Italian multicentric study on complications of laparoscopic myomectomy. *J minim invasive Gynaec* 2007;14:453-62
- Ordulu Z et Al. Disseminated peritoneal leiomyomatosis after laparoscopic supra cervical hysterectomy with characteristic molecular cytogenetic findings of uterine leiomyoma. *Genes Chromosomes Cancer* 2010;201049:1152-60
- Society of Gynecologic Oncology. SGO position statement: morcellation. Chicago: SGO; 2013. Available at <https://www.sgo.org/newsroom/position-statements-2/morcellation>. Accessed on November 11, 2014.
- American College of Obstetricians and Gynecologists. Power morcellation and occult malignancy in gynecologic surgery. Washington, DC: ACOG; 2014. Available at <http://www.acog.org/Resources-And-Publications/Task-Force-and-Work-Group-Reports/Power-Morcellation-and-Occult-Malignancy-in-Gynecologic-Surgery>. Accessed on November 22, 2014.
- De Wilde RL, Trew G. Postoperative abdominal adhesions and their prevention in gynaecological surgery. Expert consensus position. Part 2: steps to reduce adhesions. *Gynecol Surg*. 2007;4:243e253.
- Takeda A, Manabe S, Hosono S, Nakamura H. Preoperative evaluation of submucosal fibroid by virtual hysteroscopy. *J Am AssocGynecolLaparosc* 2004;11:404-409.
- Maher PJ. Endoscopic management of fibroid. *Rev GynecolPract* 2003;3:41-45.
- Donnez J, Jadoul P. What are the implications of myomas on fertility? A need for a debate? *Hum Reprod* 2002;17:1424-1430.
- Buttram and Reiter, 1981; Cicinelli et al., 1995; Richards et al., 1998; Ng and Ho, 2002).
- Ng EH, Ho PC. Doppler ultrasound examination of uterine arteries on the day of oocyte retrieval in patients with uterine myomas undergoing IVF. *Hum Reprod* 2002;17:765-770.
- Hallez JP. Single-stage total hysteroscopic myomectomies: indications, techniques, and results. *FertilSteril* 1995;63:703-708.
- Munoz JL, Jimenez JS, Hernandez C, Vaquero G, Perez Sagaseta C, Noguero R, Miranda P, Hernandez JM, De la Fuente P. Hysteroscopic myomectomy: our experience and review. *JLS* 2003;7:39-48.
- Munro MG, Critchley HO, Broder MS, Fraser IS; FIGO Working Group on Menstrual Disorders. FIGO classification system (PALM-COEIN) for causes of abnormal uterine bleeding in nongravid women of reproductive age. *Int J Gynaecol Obstet*. 2011 Apr;113(1):3-13. doi: 10.1016/j.ijgo.2010.11.011
- Lasmar RB, Barrozo PR, Dias R, Oliveira MA. Submucous myomas: a new presurgical classification to evaluate the viability of hysteroscopic surgical treatment – preliminary report. *J Minim Invasive Gynecol* 2005; 12: 308 – 311.
- McCausland VM, Fields GA, McCausland AM, Townsend DE. Tubo-ovarian abscesses after operative hysteroscopy. *J Reprod Med*. 1993;38:198-200 (III). ACOG practice bulletin No. 104: antibiotic prophylaxis for gynecologic procedures. *Obstet Gynecol*. 2009;113:1180-1189 (N/A).
- Coccia ME, Becattini C, Bracco GL, Bargelli G, Scarselli G. Intra-operative ultrasound guidance for operative hysteroscopy. A prospective study. *J Reprod Med*. 2000;45:413-418.
- Emanuel MH, Wamsteker K. The Intra Uterine Morcellator: a new hysteroscopic operating technique to remove intrauterine polyps and myomas. *J Minim Invasive Gynecol* 2005;12:62-66.
- Murakami T, Tamura M, Ozawa Y, Suzuki H, Terada Y, Okamura K. Safe techniques in surgery for hysteroscopic myomectomy. *J ObstetGynaecol Res* 2005;31:216-223.
- Phillips DR, Nathanson HG, Milim SJ, Haselkorn JS. The effect of dilute vasopressin solution on the force needed for cervical dilatation: a randomized controlled trial. *Obstet Gynecol*. 1997;89:507-511 (I).
- Indman PD. Hysteroscopic treatment of submucous myomas. *ClinObstet Gynecol*. 2006;49:811-820.
- Vilos GA. Hysteroscopic surgery: Indication, contraindications and complications. London: Taylor and Francis; 2004.
- Nappi C, Di Spiezio Sardo A, Greco E, Guida M, Bettocchi S, Bifulco G. Prevention of adhesions in gynaecological endoscopy. *Hum Reprod Update* 2007;13:379-394.

**Knowing Is Not Enough; We Must Apply.**

**Wishing Is Not Enough; We Must Do.**

**- Johann Wolfgang Von Goethe**

# Fibroids and Subfertility



## Dr. Reeta Mahey

Associate Professor, ART  
All India Institute of Medical  
Sciences, New Delhi



## Dr. Monica Gupta

Registrar, Obstetrics & Gynaecology  
All India Institute of Medical Sciences,  
New Delhi

## INTRODUCTION

Fibroids are the most common benign tumours of the female pelvis with an incidence of 20-30% among women of reproductive age group.<sup>1</sup> According to recent data, every 7-8 out of 10 women experience fibroid at least once in life time. More than 50% of all myoma are asymptomatic.

Symptomatic myomas can present with menstrual complaints, subfertility, lump abdomen or pressure symptoms due to pressure on bladder & rectum.

Prevalence of fibroid among infertile patients is about 5-10% but after excluding other causes of infertility, fibroids are responsible for 2-3% of cases presenting with infertility or sub fertility.<sup>2</sup> Management of fibroid in an infertile patient will depend upon age of patient, size, location and number of fibroids, associated symptoms, co-existence of any pelvic pathology and presence of other infertility factors.

## IMPACT OF FIBROIDS ON FERTILITY

### Location of myoma

Most important factor affecting fertility potential and pregnancy outcome is the location of myoma and its relation to myometrium and endometrium.<sup>2</sup> Previously only submucous myomas were thought to affect fertility potential.<sup>3</sup>

But in the last meta-analysis of 19 trials (6089 patients) by Sunkara et al results showed that intramural myomas not encroaching the endometrial cavity also negatively influence the fertility potential and are associated with significantly lower clinical pregnancy rate (RR=0.85; 95% CI: 0.77-0.94) and live birth rate (RR=0.79; 95% CI: 0.70-0.88).<sup>4</sup> Authors concluded that the presence of non-cavity-distorting intramural fibroids was associated with adverse pregnancy outcomes by reducing expected live birth rates.

### Size of myoma

Size of myoma is also a critical factor affecting the fertility potential and implantation.

Initial cut off for non cavity distorting intramural myoma affecting fertility was 5cm. But recently there have been studies on even smaller fibroids affecting IVF outcome.

In an observational study by Yan L et al, 249 patients with fibroid uterus were recruited for IVF ICSI. Authors concluded that intramural non-cavity distorting myoma >2.85cm negatively affect IVF outcome.<sup>5</sup>

In a recent retrospective study by Christopoulos G, the impact of non cavity distorting fibroids on IVF outcome was assessed. The study concluded that non cavity distorting intramural myomas negatively influence clinical pregnancy rate and live birth rate when compared to matched controls. The deleterious effect on IVF outcome was significant in women with 2 or more myomas or when size of myoma is >3cm. The study did not reveal any significant impact in women with myoma size < 30mm.<sup>6</sup>

## MECHANISMS OF IMPACT

The reason for impact of fibroid on reproductive potential of a female can be due to infertility, implantation failure, recurrent pregnancy loss and pregnancy complications. The possible mechanisms for poor reproductive outcome can be explained by:

- Altered anatomy – due to distorted uterine cavity, tubal blockade or kinking (especially in corneal myoma).
- Altered histology- elongation and distortion of glands and cystic glandular hyperplasia.
- Alteration in function of myometrium and endometrium- impaired blood supply, increased uterine contractility, chronic endometrial inflammation<sup>3</sup>
- Altered local endocrine & paracrine molecular mechanisms leading to release of vaso-active amines, inflammatory cytokines which impair fertility<sup>7</sup>
- Altered gamete transport potential
- Poor embryo implantation

All these factors create a hostile environment in the uterine cavity leading to reduced reproductive potential.

## EFFECT OF MYOMECTOMY ON REPRODUCTIVE POTENTIAL

One of the most important decision making is which fibroids should be removed in an

infertile patient and which can be left behind giving other infertility treatments.

Myomectomy is always associated with myometrial trauma, scarring due to dissection and suturing, adhesion formation, functional damage to endometrium, peritubal adhesions and altered tubo-ovarian relations thus leading to infertility.

So approach to a fibroid in an infertile patient should be judicious and include other factors:

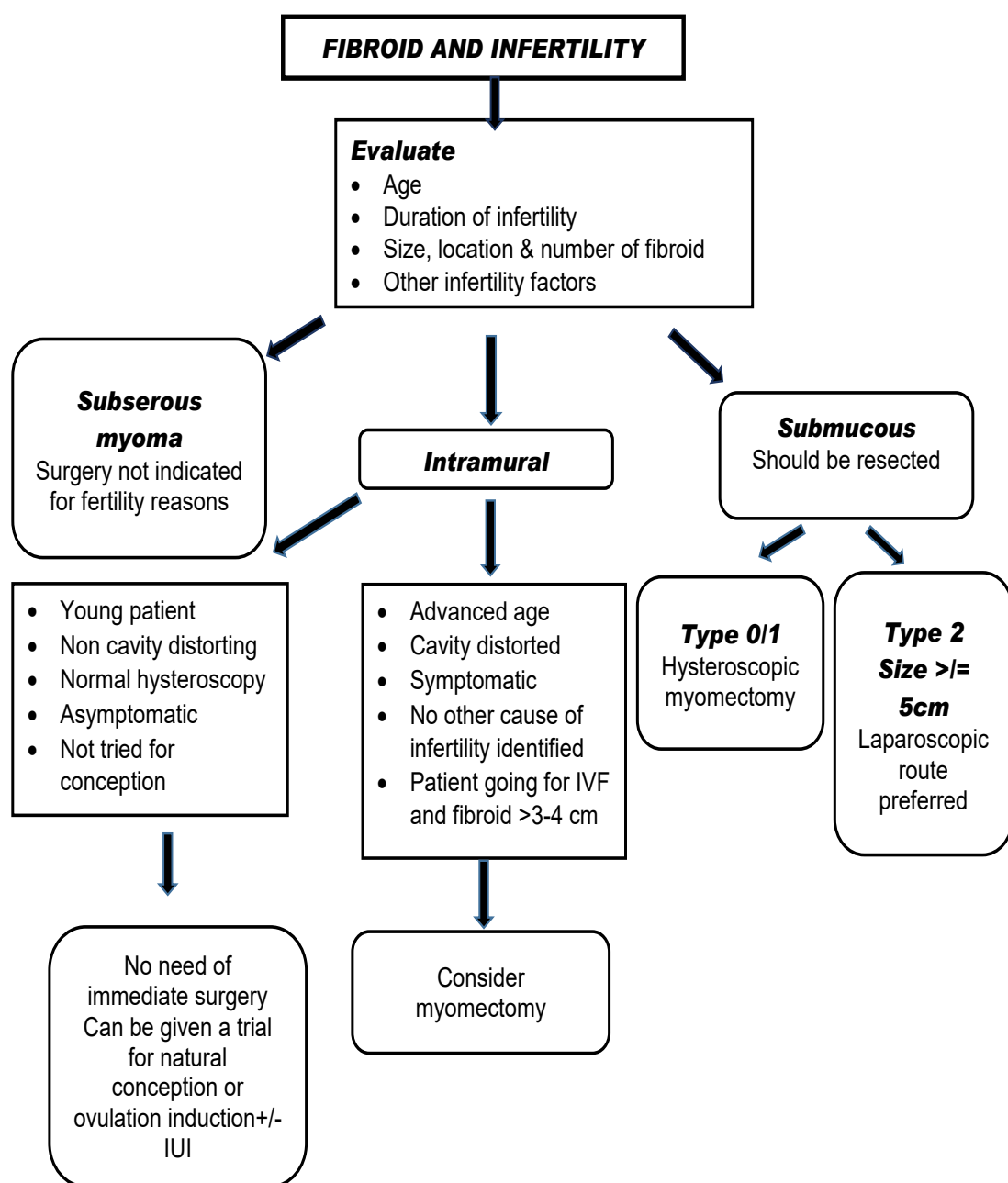
- Age of patient
- Duration of infertility
- Presence of other symptoms pertaining to fibroid
- Tubal status
- Ovarian reserve
- Husband factor
- Location, size and number of fibroids
- Other pelvic pathology

In meta-analysis by Pritts EA, it was concluded that fertility is significantly affected in submucous fibroids so myomectomy should be considered in all infertile patients presenting with submucous myoma. Subserosal fibroids do not affect fertility so myomectomy does not improve chances of conception. Effect of myomectomy on intramural myoma was not clear needing further studies.<sup>8</sup>

There is enough evidence to recommend against myomectomy in patients with non-cavity distorting myoma, intramural myoma (hysteroscopically confirmed normal endometrial cavity) irrespective of size and number of myoma. If there is no other cause of infertility (unexplained), a trial of natural conception or ovulation induction (with or without intrauterine insemination) can be given in selected patients after explaining the benefits and risks of myomectomy and risk of abortion. The management should be individualized taking all the factors in account.<sup>9</sup>

There is continuous debate on extent of impact of intramural myomas on reproductive outcome. The recent literature asserts that intramural fibroids above a certain size (>4cm), even without cavity distortion, may also negatively influence fertility. Also previous myomectomy does not appear to





**Fig. 1: Algorithm for management of fibroid in infertile patients**

negatively affect the chances

of pregnancy. Therefore, myomectomy should be considered for these fibroids in

patients with infertility especially before IVF.<sup>6</sup> It is noteworthy that intramural myomas are also associated with severe pregnancy complication, which is an additional independent indication for their removal in patients wishing pregnancy.

There is need of prospective randomized controlled trials to evaluate to clearly address the role and timing of surgical intervention especially in myomas <4cm.

According to published literature till date, exact effect of myoma on fertility and ART/ infertility outcome is not clearly known. Large prospective well controlled randomized trials are required.

### PRACTICE POINTS FOR MANAGING FIBROIDS IN INFERTILITY (FIG 1)

- All submucous myoma impair fertility, so should be resected before any infertility treatment.

- Subserous myoma don't impair fertility so should not be removed for fertility reason. Surgery should be done only after taking into account the size, associated symptoms and any other gynecological pathology.
- All intramural cavity distorting myoma should be considered for myomectomy in infertile patients before going for ART.
- Intramural non- cavity distorting myoma, treatment should be individualized. If there is no other factor for infertility, young patient, asymptomatic myoma and couple has not tried for enough duration, a trial of spontaneous conception or superovulation (with or without IUI) can be considered after proper counselling about risk and benefits of myomectomy.
- All intramural non-cavity distorting myoma >4cm size in infertile patients with no other cause of infertility, myomectomy should be considered
- Although fertility outcome is similar after laparoscopic or open approach to myomectomy, laparoscopic route should

be considered for better post- operative recovery.

- Further research is needed to assess the effect of non-cavity distorting intramural myoma on reproductive potential and cut off of size and relation to endometrium for considering for myomectomy
- Use of new diagnostic techniques such as MRI with T2 relaxation times or assessment of uterine peristalsis to identify fibroids for which surgery should be recommended. Further studies are required to utilize these techniques to manage fibroids with infertility.<sup>10</sup>

### REFERENCES

1. Serdar E & Bulun. Uterine Fibroids. NEnglMed. 2013; 369: 1344 – 1355
2. Cook H, Ezzati M, Segars JH, McCarthy K. The impact of uterine leiomyomas on reproductive outcomes. Minerva Ginecol. 2010;62:225–36.
3. Somigliana S, Vercellini P, Daguati R, Pasin R, De Giorgi O, Crosignani PG. Fibroids and female reproduction: a critical analysis of the evidence. Hum Reprod Update 2007; 13: 465–476
4. Sunkara SK, Khairy M, El-Toukhy T, Khalaf Y, Coomarasamy A. The effect of intramural fibroids without uterine cavity involvement on the outcome of IVF treatment: a systematic review and meta-analysis. Hum Reprod 2010; 25: 418–429
5. Yan L, Ding L, Li C, Wang Y, Tang R, Chen ZJ. Effect of fibroids not distorting the endometrial cavity on the outcome of in vitro fertilization treatment: a retrospective cohort study. FertilSteril. 2014 Mar;101(3):716-21.
6. Christopoulos G, Vlismas A, Salim R, Islam R, Trew G, Lavery S. Fibroids that do not distort the uterine cavity and IVF success rates: an observational study using extensive matching criteria. BJOG. 2017 Mar;124(4):615-621.
7. Mukhopadhaya N, Pokuah Asante GP, Manyonda IT. Uterine fibroids: impact on fertility and pregnancy loss. ObstetGynaecolReprod Med 2007; 17: 311-317
8. Pritts EA, Parker WH, Olive DL. Fibroids and infertility: an updated systematic review of the evidence. FertilSteril. 2009 Apr;91(4):1215-23.
9. Carranza-Mamane B, Havelock J, Hemmings R. SOGC Practice guidelines. The management of uterine fibroids in women with otherwise unexplained infertility. JObstetGynaecol Can. 2015 Mar;37(3):277-285.
10. Yoshino O, Nishii O, Osuga Y, et al. Myomectomy decreases abnormal uterine peristalsis and increases pregnancy rate. J Minimally Invasive Gynecol 2012;19:63–7.

# Newer Drugs in Medical Management of Uterine Myoma



**Dr. Taruna Bansal**

Senior Resident,  
UCMS & GTB Hospital, Delhi



**Dr. Bindiya Gupta**

Assistant Professor,  
UCMS & GTB Hospital, Delhi

## INTRODUCTION

Leiomyoma are the commonest benign tumor of female reproductive tract with an estimated incidence of 20-40% in women during their reproductive years. They are monoclonal tumors of the uterine smooth muscle cells and consist of large amounts of extracellular matrix that contain collagen, fibronectin, and proteoglycan. Even though their pathogenesis is not clearly known, there is considerable evidence that estrogen and progesterone proliferate tumor growth. Treatment includes conservative or definitive management. Conservative options include medical management, myolysis, uterine artery embolization, MR-HIFU and myomectomy. Definitive treatment is hysterectomy which is usually done in women not responding to conservative options with completed child bearing.

Due to change in lifestyle, many women are deferring childbearing to later in their reproductive years when symptoms of uterine myoma become most pronounced.<sup>1</sup> As a result, the demand for therapeutic options that preserve the uterus are becoming increasingly more relevant.

The ideal treatment for uterine myoma should satisfy three goals:

- relief of signs and symptoms,
- sustained reduction of myoma size
- maintenance or improvement of fertility

In addition, treatment should improve quality of life, have minimal side effects, be convenient for patients, and directly target myomas without systemic unintended effects. As myomas are mainly benign tumors, the most conservative options that minimize morbidity/risk and optimize outcomes should be considered.

## MEDICAL MANAGEMENT

### *GnRH analogs (GnRHa)*

GnRHa alone or more commonly with 'add-back therapy', are frequently used as temporizing measures in peri-menopausal women, or pre-operatively to reduce myoma size and render surgery safer/easier. GnRHa produce a hypogonadotropic hypogonadism state by down regulation of pituitary gland. It is used for 6 months in monthly dose to

reduce myoma volume by 30% and total uterine volume by 35%. Reduction of uterine size occurs in first 3 months. GnRHa are available as depot injections (leuprolide acetate), implantable cylinder (Goserelin) and nasal spray (Nafarelin).

Chegini et al found evidence of suppression of signal transduction pathways involving growth factors, ovarian steroids, and adhesion molecules with a resulting decrease in DNA synthesis, cell proliferation, and production of transforming growth factor- $\beta$ .<sup>2</sup> The disadvantages of GnRHa include cost, menopausal symptoms, and bone demineralization with prolonged therapy. In addition, smaller myomas may be overlooked at the time of surgery, only to recur once GnRHa is discontinued (thereby increasing the apparent risk or recurrence of myomas following myomectomy). GnRHa cannot be used as long-term therapy for myoma because of the rapid rebound growth of the myomas upon cessation of therapy.

### *GnRH antagonists*

*Cetrorelix and Ganirelix:* They cause immediate suppression of endogenous GnRH and are considered for medical treatment prior to surgery. Rapidly absorbed subcutaneously, maximum plasma concentration occurs 1-2 hour after administration. Ganirelix brings 29% reduction in myoma volume in 3 weeks.

## AROMATASE INHIBITORS

Aromatase inhibitors (AI) significantly block both ovarian and peripheral estrogen production within 1 day of treatment.<sup>3</sup> The underlying mechanism is the inhibition of the aromatase enzyme, an enzyme that catalyzes the conversion of androgenic substances into estrogens. AI have been shown to be effective against myomas in limited short-term studies with dosing regimens that included 2.5 mg per day of letrozole and 1 mg per day of anastrozole. Side effects include hot flushes, bone loss, thinning of hair, diarrhea. Due to severe side effects, they should be prescribed to women after all other options for medical or surgical management have failed.

## SELECTIVE ESTROGEN RECEPTOR MODULATORS (SERMS)

*Raloxifene:* SERMs are non-steroidal

estrogen receptor ligands that display tissue-specific agonist/antagonist estrogenic actions. They induce changes in estrogen receptors, which result in differential expression of specific estrogen-regulated genes in different tissues. It blocks estrogen activity & has the potential for therapeutic activity against myomas. Raloxifene has been showed to enhance the shrinkage of uterine myomas in postmenopausal women.<sup>4</sup> It decreases size of myoma but has no effect on uterine bleeding. However, a recent report from Italy showed that leiomyoma size in premenopausal women who were administered daily 60 mg doses of raloxifene over a 2-year period exhibited no change.<sup>5</sup>

## PROGESTERONE ANTAGONISTS

*Mifepristone:* Mifepristone is a 19-norsteroid derivative with potent anti progestational and significant anti-glucocorticoid and anti-androgenic activity. It blocks endometrial tissue growth in response to estrogen, thereby used in treatment of myoma. A study by Morales et al revealed that using mifepristone in dose of 25 mg daily for 3 months led to 50% decrease in size of uterine myoma.<sup>6</sup> However, there is no consensus about the effect of mifepristone on myoma volume and the endometrium. Its use in treatment of myomas is currently restricted to research settings.

## SELECTIVE PROGESTERONE RECEPTOR MODULATORS

Selective progesterone receptor modulator (SPRM) is a new class of progesterone receptor (PR) modulators. They exert tissue selective progesterone agonist, antagonist or mixed agonist-antagonist effects on various tissue including endometrium. Preliminary studies have showed that they reduce amount & duration of bleeding in a dose-dependant manner.

*Asoprisnil:* Asoprisnil is an orally active selective progesterone receptor modulator. It acts by downregulation of collagen synthesis through up regulation of extracellular matrix metalloproteinase inducer. Asoprisnil when used in dose of 5-25mg orally daily causes statistically significant reduction in frequency & intensity of uterine bleeding & decreases myoma size by 35-40%. Common side effects include bloating, flatulence,



**Table 1: Summary of newer drugs for management of uterine myomas**

Drug	Mechanism of Action	Advantage	Disadvantage	Myoma size	Abnormal uterine bleeding	Dosage
GnRH Agonist	Suppression of ovarian steroidogenesis-delayed pituitary downregulation	Myoma size and symptom reduction upto 50% within 3-6 months	<ul style="list-style-type: none"> <li>Reduction of estradiol levels</li> <li>Medical menopause with symptoms</li> <li>Bone loss with long-term monotherapy</li> <li>Requirement for hormonal add-back therapy</li> <li>Flare of symptoms at treatment initiation</li> <li>Rapid UF regrowth following treatment</li> </ul>	Decrease 30%	Decrease >80%	Leuprolide 3.75 mg im monthly Goserelin 3.6 mg SC monthly Nafarelin 200 µg intranasal twice daily
GnRH Antagonists	Suppression of ovarian steroidogenesis production-immediate pituitary downregulation	Reduction in myoma size 25-40% & improvement within 3 weeks	Hypoestrogenic side effects:hot flashes,vaginal dryness, headache, prolonged use associated with reduced bone mineral density	Decrease	Decrease	Cetrorelix 0.25 mg SC Ganirelix 250 mcg / 0.5 ml SC (once a week for 8 wks)
Mifepristone	Antiprogestrone effect-reduces action & no. of progesterone receptors in myomas	Improved symptoms in 60-75% with in 3 months	Hot flashes, elevated liver enzymes &endometrial hyperplasia	Decrease 25-50%	Decrease	2.5-50 mg orally daily for 3 months
Ulipristal Acetate	Selective progesterone receptor modulator	<ul style="list-style-type: none"> <li>Oral administration</li> <li>Faster control of uterine bleeding &amp; more prolonged myoma volume reduction than with GnRH agonist</li> <li>Maintenance of estradiol levels</li> </ul>	<ul style="list-style-type: none"> <li>Smaller decrease in uterine volume vs. GnRH agonist</li> <li>Non-physiological endometrial changes</li> </ul>	Decrease 30-40%	Decrease 80%	5 mg orally daily for 3 months
Asoprisnil	Selective progesterone receptor modulator	Cause significant reduction in myoma size & uterine bleeding	Bloating, flatulence, breast pain, hotflashes, night sweats	Decrease 35-40%	Decrease	5-25 mg orally per day
Raloxifene	Estrogen antagonist effects on myoma & endometrium	Decrease myoma size	Hot flushes, leg cramps, vaginal bleeding, increased risk of DVT & pulmonary embolism	Decrease	No effect	60 mg orally per day
Aromatase inhibitors	Reduce estrogen synthesis & effects	Myoma size reduced within 1-2 months	Hypoestrogenic side effects	Decrease 60-70%	No effect	Letrozole-5mg orally per day Anastrozole-1mg orally per day (for 3 months)
Gestrinone	19nortestosterone with androgenic, antiprogestrogenic, antiestrogenic, antigonadotropic activity	Amenorrhea occurs in 50-100% of women	Nausea,muscle cramps, weight gain, acne, breast hypertrophy,oily hair & skin	No effect	Decrease	1.25-2.5mg orally twice weekly for 6months
Danazol	Synthetic steroid with strong antigonadotropic activity	<ul style="list-style-type: none"> <li>Oral administration</li> </ul>	<ul style="list-style-type: none"> <li>Less effective than GnRH agonists</li> <li>High risk of adverse events: weight gain, acne, and androgenic effects</li> </ul>	Slight decrease	Decrease	200-400 mg orally twice daily

breast pain, night sweats.

**Ulipristal Acetate:** Ulipristal acetate is an orally administered agent whose biological activity is tissue selective.<sup>7</sup> On binding to the PR in target tissues, ulipristal acetate displays antagonist and partial agonist effects. Ulipristal acetate does not activate proliferation of healthy uterine tissue and, unlike progestins, it actively suppresses mammary cell proliferation in preclinical studies. In uterine myoma tissue, it induces several desirable changes, including a suppression of neovascularization and cell proliferation, as well as induction of apoptosis. It has been FDA approved for medical treatment of myomas since 2012.

The efficacy of ulipristal acetate has been demonstrated in three European phase III studies (PEARL I, II, and III).<sup>8-10</sup> These clinical trials revealed that ulipristal acetate brings about 42% reduction in the size of myoma, and improvement in heavy menstrual bleeding (98% reduction in heavy periods & 89% achieved amenorrhea) at a daily dose of 10 mg. The effects were comparable to three weeks of GnRH analog but had significantly less side effects than GnRHa. It had only 10% risk of hot flushes as compared to 40% risk of hot flushes with GnRHa. Other side effects are headache, nausea, abdominal pain. Contraindications for its use are liver disorder, uterine, cervical and breast cancers.

## OTHER HORMONAL AGENTS

**Cabergoline:** It is a dopamine agonist. Only one study, from Iran, has compared effects of cabergoline (0.5 mg once a week for 6 weeks) with GnRHa (diphereline 3.75 mg every 28, total 4 injections) which found significant myoma regression with both treatments. A preliminary study published in 2007 favored the use of cabergoline as a medical treatment of uterine myomas. The authors reported a volume reduction of about 50% in 6 weeks.<sup>11</sup> More studies are required before definitive conclusions are drawn.

**Gestrinone:** Gestrinone is a steroid that possesses anti-estrogen receptor and anti-progesterone receptor properties in various tissues, including the endometrium. A recent report from Italy evaluated the use of gestrinone in the treatment of premenopausal women with uterine myomas. The authors reported a 32%±10% reduction in uterine volume.<sup>12</sup> Gestrinone is a contraceptive agent and exhibits several unfavorable side effects, such as mild androgenicity, weight gain, seborrhea, acne, hirsutism, and occasional hoarseness.

## FUTURE DRUGS

**Vitamin D:** There is evidence that Vitamin D is an anti-fibrotic factor & inhibits growth & induces apoptosis in cultured human leiomyoma cells. Preliminary studies have suggested a strong dose-response correlation between lower serum Vitamin D levels & increased severity of uterine myomas. There

is an opportunity for potential use of Vitamin D as treatment option or for the prevention of uterine myomas.

**Pirfenidone:** It is a new drug which affects production of collagen & may have effect on cell growth factor thereby blocking growth of existing myomas. Studies are underway to establish its efficacy & safety.

**Lanreotide:** Lanreotide is a long-acting somatostatin analog & has been shown to reduce growth hormone secretion. Leiomyoma tissue expresses higher levels of IGF-I/IGF-II receptors compared to normal adjacent myometrium.<sup>13</sup> Lanreotide induced a 42% mean myoma volume reduction within a 3-month period. These results show that somatostatin analogs may potentially be a new therapy for uterine myomas. However, the lack of clinical trials which test the long-term use of somatostatin analogs along with the severe and adverse health implications such as decreased life expectancy due to accelerated heart disease may hinder its future use for leiomyoma treatment.

**Epigallocatechin gallate (EGCG)- green tea extract:** Catechins are a group of bioflavonoids that exhibit antioxidant and anti-inflammatory capacity. The major green tea catechins are epigallocatechin-3-gallate (EGCG), epigallocatechin (EGC), epicatechin-3-gallate (ECG), and epicatechin. EGCG appears to block each stage of tumor genesis by modulating signaling pathways involved in cell proliferation, transformation, inflammation, and oxidative stress, which are clearly involved in pathogenesis of various tumors including uterine myomas.<sup>14</sup> The potential effect and mechanisms of EGCG action on human leiomyoma cells was studied and it was found that EGCG inhibits their proliferation and induces apoptosis.

## CONCLUSION

The goals of uterine myoma therapy include the restoration of quality of life through rapid relief of myoma signs and symptoms, sustained reduction in tumor size, and maintenance or improvement of fertility. With more and more patients demanding a nonsurgical approach to their symptoms, there is a developing market for selective estrogen and especially progesterone receptor modulators, and exploring the role of aromatase inhibitors, vitamin D, and green tea extract. Surgical treatment for myomas should be offered to select patients with pressure symptoms and patients not responding to medical line of therapy.

## REFERENCES

1. Zimmermann A, Bernuit D, Gerlinger C, et al. Prevalence, symptoms and management of uterine myomas: an international internet-based survey of 21,746 women. *BMC Women's Health* 2012;12:6
2. Chegini N, Kornberg L. Gonadotropin releasing hormone analogue therapy alters signal transduction pathways

involving mitogen- activated protein and focal adhesion kinases in leiomyoma. *J SocGynecol Investig.*2003;10:21-26.

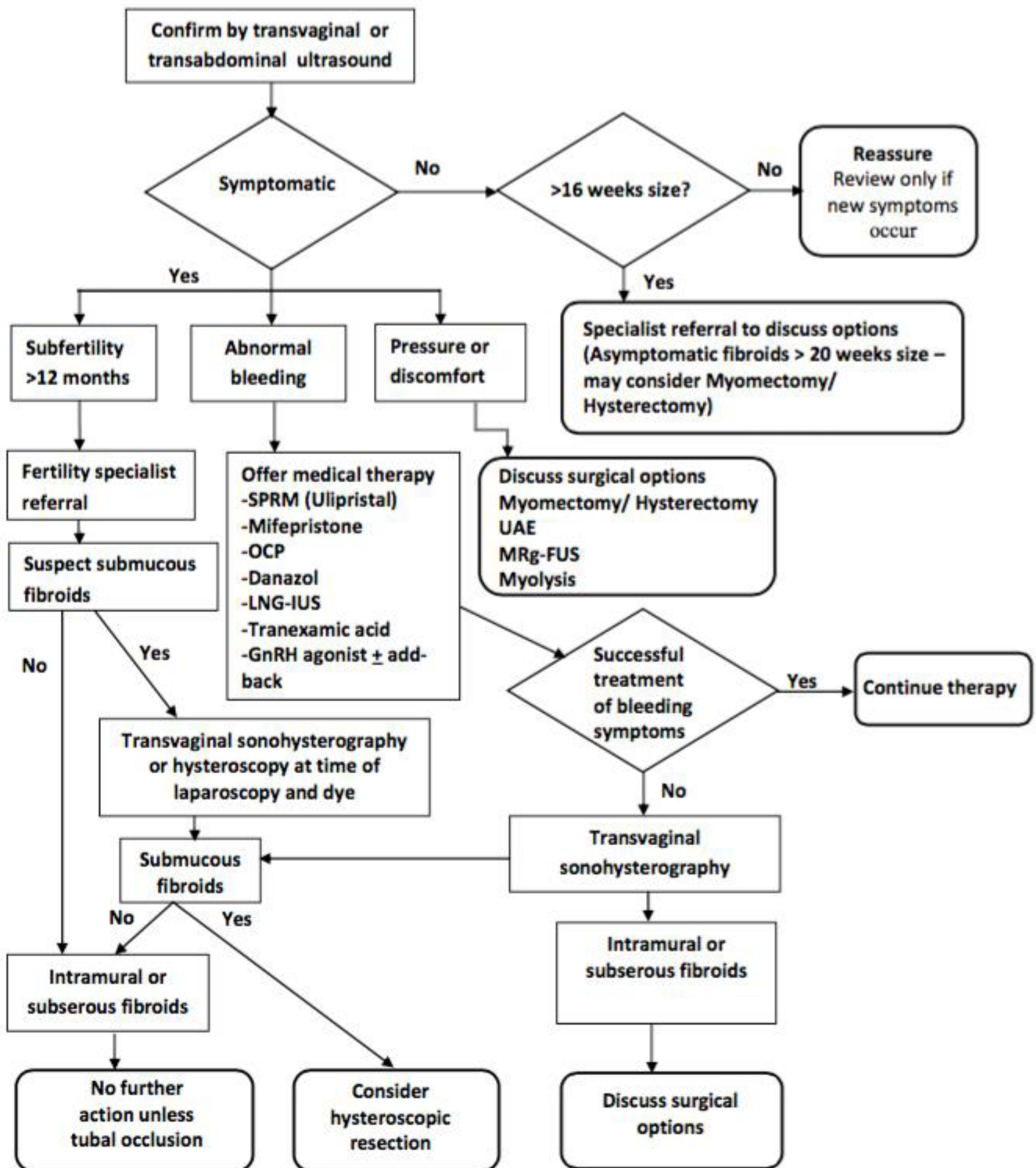
3. Fiscella K, Eisinger S. CDB-2914 for uterine leiomyomata treatment: a randomized controlled trial. *Obstet Gynecol.*2008;112(3):707;author reply 707-708
4. Palomba S, Sammartino A, Di Carlo C, Affinito P, Zullo F, Nappi C. Effects of raloxifene treatment on uterine leiomyomas in postmenopausal women. *FertilSteril.* 2001;76(1):38-43.
5. Premkumar A, Venzon DJ, Avila N, et al. Gynecologic and hormonal effects of raloxifene in premenopausal women. *FertilSteril.* 2007;88(6):1637-1644.
6. Peitsidis P, Koukoulomati A. Tranexamic acid for the management of uterine myoma tumours:a systematic review of the current evidence. *World J Clin Cases.*2014;2:893-8.
7. Chwalisz K, Perez MC, Demanno D, et al. Selective progesterone receptor modulator development and use in the treatment of leiomyomata and endometriosis. *Endocr Rev* 2005;26:423-38.
8. Donnez J, Tomaszewski J, Vazquez F, et al. Ulipristal acetate versus leuprolide acetate for uterine myomas. *N Engl J Med* 2012; 366:421-32.
9. Donnez J, Tatarchuk TF, Bouchard P, et al. Ulipristal acetate versus placebo for myoma treatment before surgery. *N Engl J Med* 2012; 366:409-20.
10. Donnez J, Vazquez F, Tomaszewski J, et al. Long-term treatment of uterine myomas with ulipristal acetate. *FertilSteril* 2014,101:1565-73.
11. Melli MS, Farzadi L, Madarek EO. Comparison of the effect of gonadotropin releasing hormone analog (Diphereline) and Cabergoline (Dostinex) treatment on uterine myoma regression. *Saudi Med J.* 2007;28(3):445-450.
12. La Marca A, Giulini S, Vito G, Orvieto R, Volpe A, Jasoni VM. Gestrinone in the treatment of uterine leiomyomata: effects on uterine blood supply. *Fert Steril.*2004;82(6):1694-1696.
13. De Leo V, la Marca A, Morgante G, Severi FM, Petraglia F. Administration of somatostatin analogue reduces uterine and myoma volume in women with uterine leiomyomata. *FertilSteril.* 2001;75(3):632-633.
14. Khan N,cAfaq F, Saleem M, Ahmad N, Mukhtar H. Targeting multiple signal pathways by green tea polyphenol – epigallocatechin-3-gallate. *Cancer Res.*2006;66(5):2500-2505.\_



# Management of Uterine Myomas: Evidence Based Algorithmic Approach



**Dr. Puneet K. Kochhar**  
 Consultant Gynecologist & IVF Specialist  
 Elixir Fertility Centre, Gujranwala Town, Delhi



MANAGEMENT ALGORITHM FOR UTERINE MYOMAS

## POINTS TO REMEMBER

### Diagnostic workup

- Asymptomatic women with fibroids where the uterine size is less than 16 weeks in size do not need further investigation but should be advised to seek help if symptoms occur.
- Although there is no evidence that asymptomatic women with a fibroid uterus greater than 20 weeks will have future health problems, hysterectomy or myomectomy is an option.
- Transvaginal sonohysterography (TVSH) should be considered prior to hysteroscopy in women where intrauterine pathology such as submucous fibroids and polyps are suspected as diagnostic hysteroscopy can be avoided in up to 40% of women.
- Transabdominal ultrasound may be required for uteri greater than 12 weeks' size as these will be beyond the reach of the transvaginal ultrasound.
- There is insufficient evidence to recommend magnetic resonance imaging (MRI) scanning as an initial diagnostic test for uterine pathology. MRI should be considered for women in whom the location or nature of the fibroids remains uncertain after TVS or who wish to avoid the possible discomforts of a TVSH.

### Medical Treatment

- Medical therapy is an option if the woman is not considered fit for surgery or does not wish to undergo surgery; however, fibroids will return to pre therapy size within 6 months of stopping therapy.
- RU486 (Mifepristone) and Selective Progesterone Receptor Modulator (Ulipristal) are effective in reducing uterine fibroid size without causing a reduction in bone mineral density.
- Gonadotrophin-releasing hormone (GnRH) analogue treatment for 3 months followed by combined 'addback' therapy

(estrogen plus progestin) result in fibroid shrinkage. Once therapy stops, the fibroids will return to pre therapy size.

### Surgical Management

- The decision whether a hysterectomy or myomectomy is undertaken is dependent on: the woman's preference, her age, desire to retain reproductive potential and the position and number of the fibroids.
- In women who do not wish to preserve fertility, hysterectomy by the least invasive approach possible may be offered as the definitive treatment for symptomatic uterine fibroids.
- Administration of GnRH analogues for 2 to 4 months prior to surgery for uterine fibroids is recommended for women with a large uterus (> 18 weeks size) or pre-operative anaemia.
- Myomectomy is an option for women who wish to preserve their uterus or enhance fertility, but carries the potential for further intervention.
- Women with submucous uterine fibroids and heavy or abnormal menstrual bleeding should be offered hysteroscopic ablation or resection as an alternative to hysterectomy.
- There is insufficient evidence to support the introduction of laser induced interstitial thermotherapy, myolysis or cryomyolysis technique.
- Embolization of uterine fibroids may be an effective alternative to myomectomy or hysterectomy but RCTs are awaited.
- Women who have fibroids detected during pregnancy should be referred to a specialist but do not require additional surveillance unless symptoms arise during the pregnancy. Most fibroids do not affect the mode of delivery and fetal growth. Possible obstetric complications include a significant increase in threatened preterm labor, pelvic pain, placental abruption,

and rarely urinary retention. Surgery during pregnancy for the removal of fibroids is not recommended because of the increased risk of hemorrhage.

## REFERENCES

1. Donnez J, Dolmans MM. Uterine fibroid management: from the present to the future. Hum Reprod Update. 2016 Nov;22(6):665-686.
2. Society of Obstetricians and Gynaecologists of Canada. SOGC clinical practice guidelines. The Management of Uterine Leiomyomas. Number 318, February 2015. J ObstetGynaecol Can 2015;37(2):157-178.
3. Puchar A, Feyeux C, Luton D, Koskas M. Therapeutic management of uterine fibroid tumors. Minerva Ginecol. 2016 Aug;68(4):466-76.
4. Marret H, Fritel X, Ouldamer L, et al; CNGOF (French College of Gynecology and Obstetrics). Therapeutic management of uterine fibroid tumors: updated French guidelines. Eur J ObstetGynecolReprod Biol. 2012 Dec;165(2):156-64.
5. Pérez-López FR, Ornat L, Ceausu I, et al; EMAS. EMAS position statement: management of uterine fibroids. Maturitas. 2014 Sep;79(1):106-16.
6. Levy BS. Modern management of uterine fibroids. ActaObstetGynecol Scand. 2008;87(8):812-23. doi: 10.1080/00016340802146912.
7. Laughlin-Tommaso SK. Alternatives to Hysterectomy: Management of Uterine Fibroids. ObstetGynecolClin North Am. 2016 Sep;43(3):397-413.
8. Istre O. Management of symptomatic fibroids: conservative surgical treatment modalities other than abdominal or laparoscopic myomectomy. Best Pract Res Clin ObstetGynaecol. 2008 Aug;22(4):735-47.

*Whether You Think  
You Can Or Think You Can't,  
You're Right.*

*- Henry Ford*



# Promising & Underutilized Non-surgical treatment for Adenomyosis: Our Experience



## Dr. Pradeep Muley

Senior Consultant Interventional Radiologist  
Fortis Ft. Lt. Rajan Dhall Hospital, New Delhi

### INTRODUCTION

Adenomyosis is a common gynecological condition characterized by the diffuse or local growth of endometrial glandular tissue, which invades the muscular layer of the uterus. This condition is primarily seen in women between 30 and 50 years of age, and it is usually the side-effect of an intrauterine procedure. The main symptoms of adenomyosis include dysmenorrhea, menorrhagia, infertility, and an enlarged uterus. The reported prevalence of adenomyosis varies from 5% to 70% because of differences in ethnicity, case selection, and diagnostic criteria.<sup>1</sup> To meet the individualized needs of patients, multiple treatment approaches have been widely used, including surgery, conservative treatment, hormone therapy, and interventional radiology or minimally invasive therapy.<sup>2,3</sup>

Uterine artery embolization (UAE) is a new treatment approach that was developed earlier this century. Since 2001, when Siskin reported using UAE to treat 15 patients with adenomyosis,<sup>4</sup> it has been tested by different institutions and determined to be an effective treatment for adenomyosis, particularly in patients who are resistant to routine medicine therapy and those who wish to preserve their uterus.<sup>5-17</sup>

### UAE PROCEDURE

In this vascular imaging-guided procedure, an interventional radiologist uses a catheter to deliver small particles to block the blood supply to targeted lesions, which are selected based on the diameter of the uterine artery and the degree of blood supply to the lesion (Figure 1). This procedure is advantageous because it is minimally invasive and maintains the patient's fertility. In theory, UAE blocks

the blood supply to both the uterus and the lesion, causing ischemic and hypoxic damage to the ectopic endometrium. The proliferated endometrial glandular cells and connective tissues will undergo necrosis and be scavenged, while the normal uterine tissue will atrophy but survive through collateral circulation. Most patients report satisfactory relief of dysmenorrhea and menorrhagia, although recurrence occurs in some cases based on long-term observations.<sup>18</sup> Therefore, it is necessary to validate the efficacy of UAE in larger patient populations and with longer follow-up periods and to identify the factors that can predict the therapeutic effects and facilitate decision-making for both trained gynecologists and patients.

In our experience, UAE was performed under the guidance of digital subtraction angiography (DSA). The right femoral artery was used as an access route in all cases. A 5.0-F RUC catheter (Cook, Bloomington, IN, USA) was placed in the right internal iliac artery, and a coaxial 3-F microcatheter (MicroFeret; Cook, Bloomington, IN, USA) was advanced into the distal uterine artery. After placing the catheter tip beyond the origin of the right cervicovaginal branch, nonionic contrast media agent was injected. Then, the microcatheter was advanced to the origin of the left cervicovaginal branch via common iliac and left internal iliac artery, and contrast media agent was injected. After obtaining both left and right uterine DSA image for vascularization analysis (Figure 2), bilateral embolization procedure was performed. The primary embolic agent was 355-500- $\mu\text{m}$ , 500-710- $\mu\text{m}$  polyvinyl alcohol (PVA) particles (Contour,

Boston Scientific, Marlborough, MA, USA) mixed with 40 mL of a 1:1 saline/contrast agent mixture to capture the angiography imaging data. This was followed by a secondary supplemental embolization with gelatin sponge pledgets. Embolization was performed until there was complete cessation of the blood flow in the ascending uterine artery and residual flow in the lower uterine segment.

### OUR RESULTS

Short-term follow-up of our study showed clinical success is about 92.6%. About 2% had treatment failure due to lack of resolution of symptoms. 92.9% patients with menorrhagia had resolution of symptoms at short-term follow-up. In terms of bulk-related symptoms before UAE, complete resolution was achieved in 34.8% of the patients, marked resolution in 47.8%, and no change in 17.4%. Short-term follow-up showed complete necrosis in 65.2% of cases of the focal type of adenomyosis and partial necrosis in 68.8% of cases of diffuse adenomyosis. Short-term follow-up also showed the rates of necrosis of adenomyotic tissue and resolution of symptoms were significantly higher in the group with the use of the combination of 250- to 355- $\mu\text{m}$  and 500- to 710- $\mu\text{m}$  PVA particles than in the groups treated with 355- to 500- $\mu\text{m}$  or 250- to 355- $\mu\text{m}$  particles.

Changes in symptom scores of menorrhagia and dysmenorrhea at long-term follow-up were about 92.2%, representing significant resolution of symptoms. 25.6% patients had additional resolution of symptoms, 43.6% of the patients had no change in symptoms. At long-term follow up the mean uterine volume decreased 27.4%. MR images at long-term follow-up revealed persistent atrophy and necrosis of the uterus in most

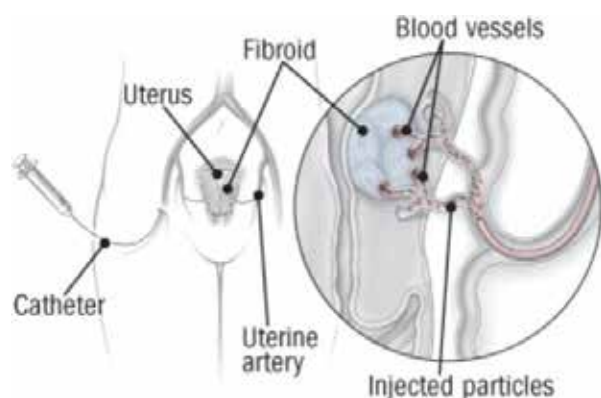


Fig.1 : Schematic diagram of Uterine Artery Embolization (UAE) through femoral route

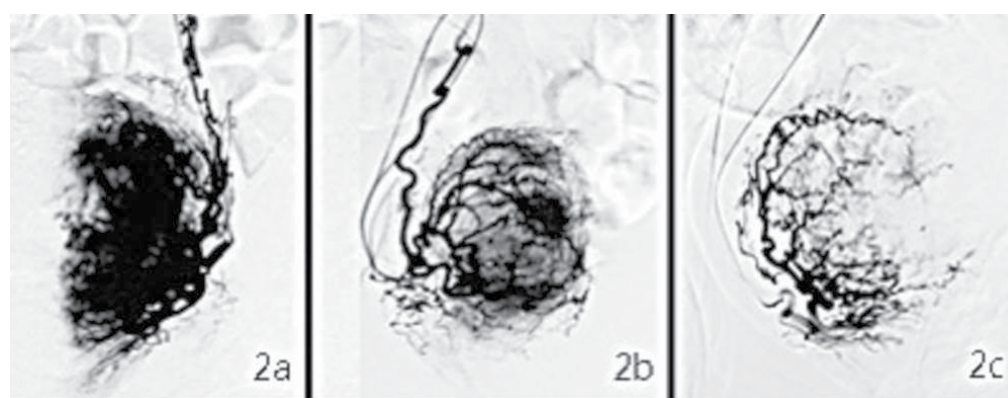


Fig. 2: Classification of vascularity abundance for adenomyosis.

2a. An example of a hypervascular adenomyosis lesion, which shows a strong imaging signal; 2b. an Isovascular lesion with a moderate signal; and 2c. a hypovascular lesion with a weak signal.

patients. Menopause happened in 1-2% during follow-up. Mean time to menopause after UAE was 2.9 years. Long-term follow-up showed that symptoms recurred few patients. The time interval between UAE and recurrence of symptoms ranged from 4 to 48 months (mean, 17.3 months). 1-2% patients may need hysterectomy because of symptom recurrence.

10% patients who achieved uneventful intrauterine pregnancies carried to term; 2% underwent elective abortion because of unwanted pregnancy. With regard to patient satisfaction with the procedure and its outcome, 70% of patients were satisfied at long-term follow-up (64.8% when failures are included). This satisfaction rate was relatively high in light of the recurrence rate of 38%.

## DISCUSSION

The results from our study suggested that UAE is an effective short- and long-term treatment for women with therapy-resistant adenomyosis. Two major symptoms presented by most patients in this study, dysmenorrhea and menorrhagia, were significantly relieved. The short-term (74.0% for dysmenorrhea and 70.9% for menorrhagia) and long-term (70.4% for dysmenorrhea and 68.8% for menorrhagia) improvement rates demonstrated in this study are consistent with the review by Popovic et al who summarized the literature available before 2011 and reported a short-term improvement rate of 83.8% after an average of 9.4 months (102 cases) and a long-term improvement rate of 64.9% after an average of 40.6 months (208 cases).<sup>18</sup> In 2012, Smeets et al studied 40 women and reported similar findings, with 29 of the 40 cases (72.5%) showing improvement.<sup>14</sup> Our current data strongly add to the evidence of UAE as an efficient method of treating adenomyosis, particularly in patients who are resistant to conventional therapy and those wish to preserve their uterus.

More importantly, various results indicated that the degree of vascularity in adenomyosis lesions is associated with improvement of symptoms after UAE, meaning that better-vascularized lesions show a better response to UAE. Therefore, the vascularity of an adenomyosis lesion may be a useful predictor for the therapeutic effect of UAE. Regarding other potential predictors of UAE treatment outcomes, Jung et al studied 119 MR images from patients with adenomyosis before UAE and suggested that the T2-weighted signal intensity ratio was significantly associated with complete necrosis after UAE.<sup>12</sup> Based on an analysis of 40 patients, Kim et al suggested that a dark MRI signal intensity (SI) of adenomyosis is the most favorable predictive factor for UAE, followed by a low SI, while a heterogeneous SI or an SI equal to that of the myometrium is an unfavorable predictive factor.<sup>10</sup> Based on these findings, the pre-operational MRI signal can be a useful predictor of necrosis in adenomyosis lesions.

In our experience as well, vascularity of adenomyosis lesions detected through

angiography is a reliable outcome predictor, directly reinforce the previous findings. Interestingly, studies have suggested that the presence or absence of fibroids in addition to adenomyosis did not affect the clinical outcomes of UAE. Although UAE has showed a satisfactory therapeutic effect against adenomyosis in the short and long term, recurrence is an important prognostic factor that researchers cannot neglect.

## CONCLUSION

We found that UAE is an effective treatment for symptomatic adenomyosis with a reasonable long term success rate. However, given a 20% rate of treatment failure and recurrence, all patients should be counseled before the procedure about the possibility of treatment failure and need for hysterectomy. We believe UAE can be used as the primary treatment and as an alternative to hysterectomy, despite the possibility of symptom recurrence. A low complication rate, short hospital stay, and rapid recovery time are other favorable features of UAE.

## REFERENCES

1. Taran FA, Stewart EA, Brucker S. Adenomyosis: Epidemiology, Risk Factors, Clinical Phenotype and Surgical and Interventional Alternatives to Hysterectomy. *Geburtshilfe Frauenheilkd.* 2013;73(9):924–31. pmid:24771944; PubMed Central PMCID: PMC3859152.
2. Levгур M. Therapeutic options for adenomyosis: a review. *Arch Gynecol Obstet.* 2007;276(1):1–15. pmid:17186255.
3. Streuli I, Dubuisson J, Santulli P, de Ziegler D, Batteux F, Chapron C. An update on the pharmacological management of adenomyosis. *Expert Opin Pharmacother.* 2014;15(16):2347–60. pmid:25196637.
4. Siskin GP, Tublin ME, Stainken BF, Dowling K, Dolen EG. Uterine artery embolization for the treatment of adenomyosis: clinical response and evaluation with MR imaging. *AJR Am J Roentgenol.* 2001;177(2):297–302. pmid:11461849.
5. Toh CH, Wu CH, Tsay PK, Yeow KM, Pan KT, Tseng JH, et al. Uterine artery embolization for symptomatic uterine leiomyoma and adenomyosis. *J Formos Med Assoc.* 2003;102(10):701–6. pmid:14691595.
6. Kitamura Y, Allison SJ, Jha RC, Spies JB, Flick PA, Ascher SM. MRI of adenomyosis: changes with uterine artery embolization. *AJR Am J Roentgenol.* 2006;186(3):855–64. pmid:16498121.
7. Kim MD, Kim S, Kim NK, Lee MH, Ahn EH, Kim HJ, et al. Long-term results of uterine artery embolization for symptomatic adenomyosis. *AJR Am J Roentgenol.* 2007;188(1):176–81. pmid:17179361.
8. Lohle PN, De Vries J, Klazen CA, Boekkooi PF, Vervest HA, Smeets AJ, et al. Uterine artery embolization for symptomatic adenomyosis with or without uterine leiomyomas with the use of calibrated tris-acryl gelatin microspheres: midterm

clinical and MR imaging follow-up. *Journal of Vascular and Interventional Radiology.* 2007;18(7):835–41. pmid:17609441

9. Bratby MJ, Walker WJ. Uterine artery embolisation for symptomatic adenomyosis—mid-term results. *Eur J Radiol.* 2009;70(1):128–32. pmid:18280686.
10. Kim MD, Kim YM, Kim HC, Cho JH, Kang HG, Lee C, et al. Uterine artery embolization for symptomatic adenomyosis: a new technical development of the 1-2-3 protocol and predictive factors of MR imaging affecting outcomes. *J Vasc Interv Radiol.* 2011;22(4):497–502. pmid:21377897.
11. Froeling V, Scheurig-Muenkler C, Hamm B, Kroencke TJ. Uterine artery embolization to treat uterine adenomyosis with or without uterine leiomyomata: results of symptom control and health-related quality of life 40 months after treatment. *Cardiovasc Intervent Radiol.* 2012;35(3):523–9. pmid:21850565.
12. Jung DC, Kim MD, Oh YT, Won JY, Lee DY. Prediction of early response to uterine arterial embolisation of adenomyosis: value of T2 signal intensity ratio of adenomyosis. *Eur Radiol.* 2012;22(9):2044–9. pmid:22527376.
13. Liang E, Brown B, Kirsop R, Stewart P, Stuart A. Efficacy of uterine artery embolisation for treatment of symptomatic fibroids and adenomyosis—an interim report on an Australian experience. *Aust N Z J Obstet Gynaecol.* 2012;52(2):106–12. pmid:22221154.
14. Smeets AJ, Nijenhuis RJ, Boekkooi PF, Vervest HA, van Rooij WJ, Lohle PN. Long-term follow-up of uterine artery embolization for symptomatic adenomyosis. *Cardiovasc Intervent Radiol.* 2012;35(4):815–9. pmid:21717251.
15. Jang D, Kim MD, Lee SJ, Kim IJ, Park SI, Won JY, et al. The effect of uterine artery embolization on premenstrual symptoms in patients with symptomatic fibroids or adenomyosis. *J Vasc Interv Radiol.* 2014;25(6):833–8 e1. pmid:24657088.
16. Bae SH, Kim MD, Kim GM, Lee SJ, Park SI, Won JY, et al. Uterine Artery Embolization for Adenomyosis: Percentage of Necrosis Predicts Midterm Clinical Recurrence. *J Vasc Interv Radiol.* 2015;26(9):1290–6 e2. pmid:26074028.
17. Nijenhuis RJ, Smeets AJ, Morpurgo M, Boekkooi PF, Reuwer PJ, Smink M, et al. Uterine artery embolisation for symptomatic adenomyosis with polyzene F-coated hydrogel microspheres: three-year clinical follow-up using UFS-QoL questionnaire. *Cardiovasc Intervent Radiol.* 2015;38(1):65–71. pmid:24692030.
18. Popovic M, Puchner S, Berzaczy D, Lammer J, Bucek RA. Uterine artery embolization for the treatment of adenomyosis: a review. *J Vasc Interv Radiol.* 2011;22(7):901–9; quiz 9. pmid:21570318.





## Dr. Sharda Patra

Professor, Obstetrics & Gynecology

Lady Hardinge Medical College & SSK Hospital, New Delhi

### 1. A New Paradigm for Uterine Fibroid Treatment: Transcervical, Intrauterine Sonography-Guided Radiofrequency Ablation of Uterine Fibroids with the Sonata System

Toub, D. B.

*Curr Obstet Gynecol Rep.* 2017; 6(1): 67–73

**OBJECTIVE:** This article provides the current evidence related to transcervical radiofrequency ablation of uterine fibroids under integrated intrauterine sonography guidance (the Sonata System).

**METHODS:** Published data based on multicentric study on the treatment of fibroids on a total of 50 women (92 fibroids) with the Sonata System has demonstrated significant median reductions in total (73.3%) and perfused (73.3%) uterine fibroid volume, menstrual bleeding (72.3%), symptom severity (62.5%), and improvements in health-related quality of life (127%) at 12 months post-ablation.

A clinical trial under an FDA Investigational Device Exemption is in progress.

**SUMMARY:** The Sonata System is a promising treatment modality for uterine fibroids. As an incisionless, minimally invasive treatment that does not require general anesthesia or hospitalization, it has the potential for redefining the current paradigm for management of symptomatic fibroids.

### 2. Impact and clinical significance of Embosphere microsphere artery embolization therapy in serum VEGF expression level of women patients with uterine fibroids

Ge HX, Xu W, Du DQ, Wang AJ

*Eur Rev Med Pharmacol Sci.* 2017 Mar;21(5):913-921.

**OBJECTIVE:** We aimed to investigate the effect of Embosphere microsphere artery embolization on the serum level of vascular endothelial growth factor (VEGF) in patients with uterine fibroid.

**METHODS:** From March 2014 to December 2015, 128 women in child-bearing age with uterine intramural fibroids were enrolled in the patient group. At the same time, 128 healthy cases in child-bearing age were randomly selected and enrolled in the control group. Enzyme-linked immunosorbent assay

was used to measure the serum level of VEGF, and immunohistochemical staining method was used to study the expression of VEGF in the uterine fibroids. Embosphere microsphere artery embolization surgery was performed on cases in the patient group.

**RESULTS:** The serum level of VEGF in the patient group was significantly higher than that of the control group. Immunohistochemical staining results showed that in the control group, VEGF expression level in uterine fibroid tissue was significantly higher. Compared with before the treatment, tumor diameter in the patient group reduced significantly 3 months after the treatment. Erythrocyte count, hemoglobin, and menstrual blood volume increased significantly 6 months after treatment.

**CONCLUSION:** Serum VEGF level can be considered as a marker for uterine fibroid, and by using VEGF as a marker we can increase the probability of early diagnosis. We showed that, compared with hysterectomy, Embosphere microsphere embolization had an evident advantage and might be an excellent candidate to replace hysterectomy.

### 3. Magnetic Resonance Imaging-Guided Focused Ultrasound Surgery for the Treatment of Symptomatic Uterine Fibroids: our experience on patients' eligibility

Geraci L, Napoli A, Catalano C, Midiri M, Gagliardo C

*Case Reports in Radiology.* 2017; 11 pages. <https://doi.org/10.1155/2017/2520989>

**BACKGROUND:** Uterine fibroids, the most common benign tumor in women of childbearing age, may cause symptoms including pelvic pain, menorrhagia, dysmenorrhea, pressure, urinary symptoms, and infertility. Various approaches are available to treat symptomatic uterine fibroids. Magnetic Resonance-guided Focused Ultrasound Surgery (MRgFUS) represents a recently introduced noninvasive safe and effective technique that can be performed without general anesthesia, in an outpatient setting.

**METHODS:** We review the principles of MRgFUS, describing patient selection criteria for the treatments performed at our center and we present a series of five selected patients with symptomatic uterine fibroids treated with this not yet widely known

technique, showing its efficacy in symptom improvement and fibroid volume reduction. We treated five cases of adult females with symptomatic uterine fibroids treated with MRgFUS. The cases we presented had some distinctive features of interest ranging from technical measures which enabled establishing a safe treatment pathway to uncommon posttreatment findings and demonstration of variable clinical response that does not always correlate with the percentage of tumor ablation calculated.

**RESULTS:** As for all newly introduced therapeutic procedures, many points will be clarified only with further investigations, additional research, and multicenter studies. MRgFUS represents an effective and almost noninvasive approach that may be used as a fertility-preserving technique for the treatment of symptomatic uterine fibroids. It is a disruptive technology with a remarkable potential in terms of improved outcomes, safety and efficacy, faster recovery, and sustained symptomatic relief and, in the near future, it could cause a sea change in current clinical surgical care.

### 4. Power Morcellation Using a Contained Bag System

Steller C, Cholkeri-Singh A, Sasaki K, Miller CE.

*JSLs : Journal of the Society of Laparoendoscopic Surgeons.* 2017;21(1):e2016.00095. doi:10.4293/JSLs.2016.00095.

**BACKGROUND AND OBJECTIVES:** The well-known advantages of minimally invasive surgery make the approach well suited for hysterectomy and other gynecological procedures. The removal of specimens excised during surgery has been a challenge that has been answered by the use of power morcellation. With this study we sought to assess the feasibility of power morcellation within a specimen bag.

**METHODS:** This was a retrospective cohort study including patients from a private practice in suburban Chicago, Illinois, who underwent contained electromechanical power morcellation during a laparoscopic or robot-assisted hysterectomy or myomectomy from May 2014 through December 2015. Contained power morcellation was performed with the Espiner EcoSac 230 (Espiner Medical Ltd., North Somerset,

United Kingdom) specimen bag. Descriptive statistics were performed for both categorical and continuous data.

**RESULTS:** Of the 187 procedures performed, 73.8% were myomectomies, and 26.2% were hysterectomies. The patients' mean age was 40 (range, 25–54) years and mean body mass index was 28.7 (range, 17.3–57.6). The average specimen weight was 300 g, with the largest weighing 2134 g. Estimated blood loss averaged 98.4 mL. The postoperative admission rate was 12.3%, most of which were due to nausea and urinary retention. Seventeen patients (9.1%) had postoperative complications, most of which were minor, and 4 (2.1%) were readmitted. There were no bag failures or complications that were due to the use of the specimen bag or to power morcellation.

**CONCLUSIONS:** Performing electromechanical power morcellation within the Espiner EcoSac 230 specimen bag was successfully performed in 187 patients with no bag-related complications. This method of contained power morcellation is feasible, reliable, and reproducible, even for a large specimen.

#### 5. European Society of Gynecological Oncology Statement on Fibroid and Uterine Morcellation

Halaska MJ, Haidopoulos D, Guyon F, Morice P, Zapardiel I, Kesic V; ESGO Council

*Int J Gynecol Cancer.* 2017;27(1):189-192. doi: 10.1097/IGC.0000000000000911.

Recently, there has been an intense discussion about the issue of fibroid and uterine morcellation in relation to the risk of unrecognized uterine sarcoma spread. Morcellation can negatively influence the prognosis of patients, and transecting the specimen into pieces prevents the pathologist from performing proper disease staging. Many societies have published their statements regarding this issue. The European Society for Gynecological Oncology has established a working group of clinicians involved in diagnostics and treatment of oncogynecological patients to provide a statement from the oncological point of view. Leiomyosarcomas and undifferentiated endometrial sarcomas have generally a dismal prognosis, whereas low-grade endometrial stromal sarcomas and adeno-sarcomas have variable prognosis based on their stage.

A focus on the detection of patients at risk of having a sarcoma should be mandatory before every surgery where morcellation is planned by evaluation of risk factors (African American descent, previous pelvic irradiation, use of tamoxifen, rapid lesion growth particularly in postmenopausal patients) and exclusion of patients with any suspicious ultrasonographic signs. Preoperative endometrial biopsy should be mandatory, although the sensitivity to detect sarcomas is low. An indication for myomectomy should be used only in patients with pregnancy plans; otherwise en bloc hysterectomy is preferred in both

symptomatic and postmenopausal patients. Eliminating the technique of morcellation could lead to an increased morbidity in low-risk patients; therefore, after thorough preoperative evaluation and discussion with patients, morcellation still has its place in the armamentarium of gynecologic surgery.

#### 6. Different dosages of mifepristone versus enantone to treat uterine fibroids. A multicenter randomized controlled trial

Liu C, Lu Q, Qu H, Geng L, Bian M, Huang M, Wang H, Zhang Y, Wen Z, Zheng S, Zhang Z.

*Medicine.* 2017; 96(7): (e6124) doi: 10.1097/MD.00000000000006124.

**BACKGROUND:** To evaluate the efficacy and safety of 10 mg and 25 mg mifepristone per day compared with 3.75 mg enantone (gonadotropin-releasing hormone analog) in treating uterine fibroids.

**METHODS:** This is a multicenter randomized controlled trial. A total of 501 subjects with symptomatic uterine fibroids were enrolled and randomized into the group of 10 mg, 25 mg mifepristone and 3.75 mg enantone, (with 307, 102 and 92 subjects respectively), with 458 subjects completed the treatment. Three months of daily therapy with oral mifepristone (at a dose of either 10 mg or 25 mg) or once-monthly subcutaneous injections of enantone (at a dose of 3.75 mg) were used. Change in volume of the largest uterine fibroid was the primary efficacy variable, and secondary efficacy variables included changes in anemia and relevant symptom. Safety evaluation included the analyses of adverse events, laboratory values, and relevant endometrial changes.

**RESULTS:** After three months of treatment, the mean volume of the largest leiomyoma was significantly reduced by mifepristone 10 mg or 25 mg or enantone 3.75 mg (40.27%, 42.59% and 44.49% respectively) ( $P < 0.0001$ ). Percentage change from baseline in largest leiomyoma volume was not statistically significant among the three groups ( $P = 0.1057$ ). Most of the patients in all groups experienced amenorrhea after the treatment. There were also significant elevations in red blood cell count, hemoglobin and hematocrit ( $P < 0.0001$ ), and significant reductions in prevalence of dysmenorrhea, pelvic pressure, non-menstrual abdominal pain ( $P < 0.0001$ ) in each group, while no significant difference among the three groups. All study medications are well-tolerated, and no serious adverse event was reported. Treatment-related adverse event rate was significantly lower in mifepristone 10 mg group, compared to Enantone 3.75 mg group (13.59% vs. 32.58%,  $P = 0.0002$ ). In both mifepristone groups, estradiol levels were maintained in the premenopausal range, whereas patients in the enantone group had a significant reduction to postmenopausal levels ( $P < 0.0001$ ).

**CONCLUSION:** 10 mg is as effective as 25 mg mifepristone and 3.75 mg enantone with minimal drug-related side effects, and may provide an alternative for clinical

application, especially for patient who are in perimenopause with uterine fibroids.

#### 7. Selective progesterone receptor modulators (SPRMs) for uterine fibroids

Murji A, Whitaker L, Chow TL, Sobel ML.

*Cochrane Database of Systematic Reviews.* 2017, Issue 4. Art. No.: CD010770. DOI: 10.1002/14651858.CD010770.pub2.

**OBJECTIVE:** To evaluate the effectiveness and safety of SPRMs for treatment of premenopausal women with uterine fibroids.

**METHODS:** Included studies were randomized controlled trials (RCTs) of premenopausal women with fibroids who were treated for at least three months with a SPRM.

**RESULTS:** We included in the review 14 RCTs with a total of 1215 study participants. We included in the meta-analysis 11 studies involving 1021 study participants: 685 received SPRMs and 336 were given a control intervention (placebo or leuprolide). Investigators evaluated three SPRMs: mifepristone (five studies), ulipristal acetate (four studies) and asoprisnil (two studies).

#### SPRM versus placebo

SPRM treatment resulted in improvements in fibroid symptom severity (MD -20.04 points, 95% confidence interval (CI) -26.63 to -13.46; four RCTs, 171 women,  $I^2 = 0\%$ ; moderate-quality evidence) and health-related quality of life (MD 22.52 points, 95% CI 12.87 to 32.17; four RCTs, 200 women,  $I^2 = 63\%$ ; moderate-quality evidence) on the Uterine Fibroid Symptom Quality of Life Scale (UFS-QoL, scale 0 to 100). Women treated with an SPRM showed reduced menstrual blood loss on patient-reported bleeding scales, although this effect was small (SMD -1.11, 95% CI -1.38 to -0.83; three RCTs, 310 women,  $I^2 = 0\%$ ; moderate-quality evidence),

along with higher rates of amenorrhoea (29 per 1000 in the placebo group vs 237 to 961 per 1000 in the SPRM group; OR 82.50, 95% CI 37.01 to 183.90; seven RCTs, 590 women,  $I^2 = 0\%$ ; moderate-quality evidence), compared with those given placebo. We could draw no conclusions regarding changes in pelvic pain owing to variability in the estimates. With respect to adverse effects, SPRM associated endometrial changes were more common after SPRM therapy than after placebo (OR 15.12, 95% CI 6.45 to 35.47; five RCTs, 405 women,  $I^2 = 0\%$ ; low-quality evidence).

#### SPRM versus leuprolide acetate

In comparing SPRM versus other treatments, two RCTs evaluated SPRM versus leuprolide acetate. One RCT reported primary outcomes. No evidence suggested a difference between SPRM and leuprolide groups for improvement in quality of life, as measured by UFS-QoL fibroid symptom severity scores (MD -3.70 points, 95% CI -9.85 to 2.45; one RCT, 281 women; moderate-quality evidence) and health-related quality of life scores (MD 1.06 points, 95% CI -5.73 to 7.85; one RCT, 281



women; moderate-quality evidence). It was unclear whether results showed a difference between SPRM and leuprolide groups for reduction in menstrual blood

loss based on the pictorial blood loss assessment chart (PBAC), as confidence intervals were wide (MD 6 points, 95% CI -40.95 to 50.95; one RCT, 281 women; low-quality evidence), or for rates of amenorrhoea (804 per 1000 in the placebo group vs 732 to 933 per 1000 in the SPRM group; OR 1.14, 95% CI 0.60 to 2.16; one RCT, 280 women; moderate-quality evidence). No evidence revealed differences between groups in pelvic pain scores based on the McGill Pain Questionnaire (scale 0 to 45) (MD -0.01 points, 95% CI -2.14 to 2.12; 281 women; moderate-quality evidence). With respect to adverse effects, SPRM-associated endometrial changes were

more common after SPRM therapy than after leuprolide treatment (OR 10.45, 95% CI 5.38 to 20.33; 301 women; moderate-quality evidence).

**CONCLUSIONS:** Short-term use of SPRMs resulted in improved quality of life, reduced menstrual bleeding and higher rates of amenorrhoea than were seen with placebo. Thus, SPRMs may provide effective treatment for women with symptomatic fibroids. Evidence derived from one RCT showed no difference between leuprolide acetate and SPRM with respect to improved quality of life and bleeding symptoms. Evidence was insufficient to show whether effectiveness was different between SPRMs and leuprolide. Investigators more frequently observed SPRM-associated endometrial changes in women treated with SPRMs than in those treated with placebo or leuprolide acetate. As noted above, SPRM-associated endometrial changes are benign, are not related to cancer and are not precancerous. Reporting bias may impact the conclusion of this meta-analysis. Well-designed RCTs comparing SPRMs versus other treatments are needed.

#### 8. The association between ultrasound-estimated visceral fat deposition and uterine fibroids: an observational study

Ciavattini A, Delli Carpini G, Moriconi L, Clemente N, Orici F, Boschi AC, Montik N, Mazzanti L. T

*Gynecological Endocrinology. 2017; 21:1-4.*

**BACKGROUND:** Uterine fibroids are the most common neoplasm of the genital tract in reproductive women. Obesity holds a role as risk factor for uterine fibroids, through hormonal and inflammatory mechanisms. Visceral fat is a hormonally active tissue, so an increase in visceral fat may be considered as a risk factor, through the increased production of inflammatory mediators.

**OBJECTIVE:** To evaluate the association between the presence of uterine fibroids and fat tissue distribution, and to assess the efficacy of both anthropometric and instrumental indicators, in particular the sonographic measurement of preperitoneal fat thickness (PFT) and subcutaneous fat

thickness (SFT). Study group consisted of childbearing-age women with at least one uterine fibroid with a diameter  $\geq 10$  mm ( $n=71$ ), all the childbearing-age women who access to the outpatient service of our institution in the same period, without evidence of uterine fibroids, constituted the control group ( $n=145$ ).

**RESULTS:** A significant difference in BMI ( $p=0.0034$ ), PFT ( $p<0.0001$ ), and SFT ( $p=0.0003$ ) emerged. At the multivariate analysis, only PFT showed an independent significant association with the presence of uterine fibroids ( $p<0.0001$ ). The ROC curve analysis identified a cut-off value of 6.7 mm of PFT as discriminator for the presence of uterine fibroids.

#### 9. Magnetic resonance texture parameters are associated with ablation efficiency in MR-guided high-intensity focused ultrasound treatment of uterine fibroids

Hocquelet A, Denis de Senneville B, Frulio N, Salut C, Bouzgarrou M, Papadopoulos P, Trillaud H.

*Int J Hyperthermia. 2016 Oct 28;1-8. [Epub ahead of print]*

**OBJECTIVES:** The objective of this study is to assess the association between texture parameter analysis derived from T2-weighted images and efficiency of magnetic resonance-guided focussed ultrasound (MRgFUS) ablation for the treatment of uterine fibroids.

**METHODS:** Fifty-five women treated by MRgFUS were included in this retrospective analysis. Texture parameters were calculated using three 2D regions of interest placed on three consecutive slices on the same sagittal 3D T2-weighted images obtained at the beginning of MRgFUS ablation. Using uni- and multi-variate linear regression, texture parameters, fibroids/muscular T2W ratio (T2Wr), Funaki type, and fibroid depth were correlated with ablation efficiency, defined as the ratio of non-perfused volume (NPV) on post-treatment contrast-enhanced MRI by total volume of treatment-cell sizes used. Inter-rater reproducibility for texture analysis was assessed using variation coefficients.

**RESULTS:** The mean total treatment cell volume was 49.5 ( $\pm 30$ ) ml, corresponding to a mean NPV of 57.2 ( $\pm 57$ ) ml (28%). The mean ablation efficiency was 1.14 ( $\pm 0.7$ ), with a range of 0.03–3.6. In addition to fibroid/muscular T2Wr, seven of the 14 texture parameters were significantly correlated with ablation efficiency: mean signal intensity ( $p=.047$ ); Skewness ( $p=.03$ ); Kurtosis ( $p=.015$ ); mean uniformity ( $p=.052$ ); mean sum of square ( $p=.045$ ); mean sum entropy ( $p=.021$ ) and mean entropy ( $p=.051$ ). In multivariate linear regression, fibroid/muscular T2Wr and sum of entropy were associated with ablation efficiency. The inter-rater coefficient of variation for sum entropy was 2.6%.

**CONCLUSIONS:** Uterine fibroid texture parameters provide complementary information to T2Wr, and are associated with MRgFUS efficiency. Mean sum entropy

is negatively correlated with MRgFUS efficiency ( $\rho=-0.307$ ,  $p=.021$ ). Fibroids/muscular T2-weighted ratio and entropy are associated with MRgFUS efficiency. Texture parameters are better predictors of MRgFUS efficiency than Funaki type. Fibroid MR texture analysis can improve patient selection for MRgFUS.

#### 10. Evaluating the role of race and medication in protection of uterine fibroids by type 2 diabetes exposure

Velez Edwards DR, Hartmann KE, Wellons M, Shah A, Xu H, Edwards TL

*BMC Womens Health. 2017;17(1):28. doi: 10.1186/s12905-017-0386-y.*

**BACKGROUND:** Uterine fibroids (UF) affect 77% of women by menopause, and account for \$9.4 billion in annual healthcare costs. Type-2-diabetes (T2D) has inconsistently associated with protection from UFs in prior studies. To further evaluate the relationship between T2D and UFs we tested for association between T2D and UF risk in a large clinical population as well as the potential differences due to T2D medications and interaction with race.

**METHODS:** This nested case-control study is derived from a clinical cohort. Our outcome was UF case-control status and our exposure was T2D. UF outcomes and T2D exposure were classified using validated electronic medical record (EMR) algorithms. Logistic regression, adjusted for covariates, was used to model the association between T2D diagnosis and UF risk. Secondary analyses were performed evaluating the interaction between T2D exposure and race and stratifying T2D exposed subjects by T2D medication being taken.

**RESULTS:** We identified 3,789 subjects with UF outcomes (608 UF cases and 3,181 controls), 714 were diabetic and 3,075 were non-diabetic. We observed a nominally significant interaction between T2D exposure and race in adjusted models (interaction  $p=0.083$ ). Race stratified analyses demonstrated more protection by T2D exposure on UF risk among European Americans (adjusted odds ratio [aOR] = 0.50, 95% CI 0.35 to 0.72) than African Americans (aOR = 0.76, 95% CI 0.50 to 1.17). We also observed a protective effect by T2D regardless of type of T2D medication being taken, with slightly more protection among subjects on insulin treatments (European Americans aOR = 0.42, 95% CI 0.26 to 0.68; African Americans aOR = 0.60, 95% CI 0.36 to 1.01).

**CONCLUSIONS:** These data, conducted in a large population of UF cases and controls, support prior studies that have found a protective association between diabetes presence and UF risk and is further modified by race. Protection from UFs by T2D exposure was observed regardless of medication type with slightly more protection among insulin users. Further mechanistic research in larger cohorts is necessary to reconcile the potential role of T2D in UF risk.

# Brain Teasers

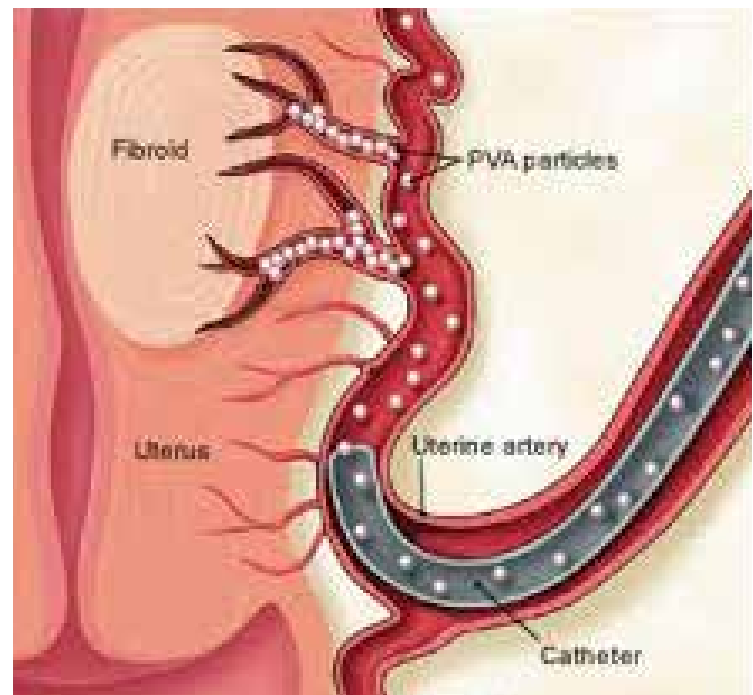
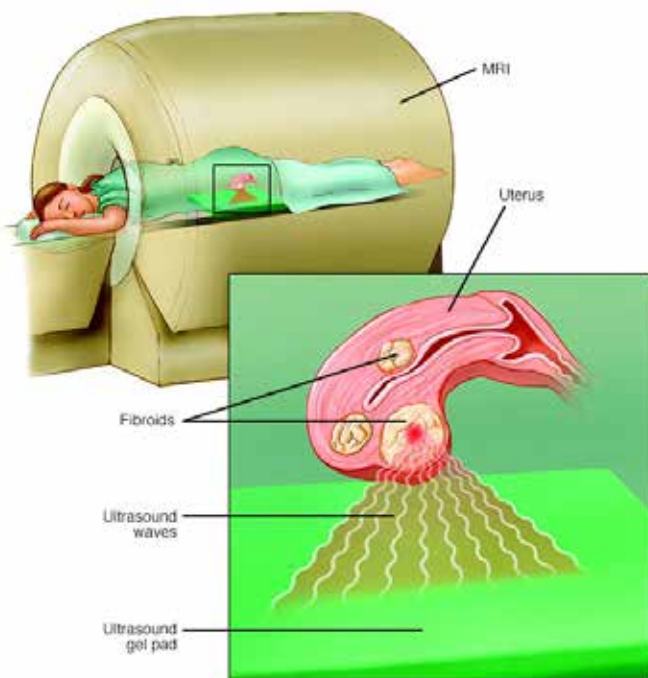


**Dr. Abha Rani Sinha**

Associate Professor, Obst & Gynae, Patna Medical College, Patna,  
Chairperson Quiz Committee FOGSI (2015-2017)

Q. 1. Identify this non-invasive method of management leiomyoma?

Q. 2. Identify this technique of managing fibroids? What are components the post procedure syndrome?



Q. 3. Which diagnostic modality is best for myoma mapping?

Q. 4. What are the parameters for STEP-W or lasmar's presurgical hysteroscopic classification for submucous fibroids?

Q. 5. LNG-IUS is not recommended for treatment of fibroid, if uterine size is more than 12 weeks.

## ANSWERS TO BRAIN TEASERS – JUNE ISSUE

1. Amniotic fluid sludge
2. Wurm's procedure
3. (b) Preterm Premature Rupture of Membranes
4. (c) FMS-like tyrosine kinase receptor 1
5. Necrotising enterocolitis